Pemphigus 29

Masayuki Amagai

Synonyms: ▪ Fogo selvagem: endemic pemphigus foliaceus; Brazilian pemphigus ▪ Pemphigus erythematosus: Senear–Usher syndrome ▪ IgA pemphigus: intercellular IgA dermatosis; intraepidermal neutrophilic IgA dermatosis; intercellular IgA vesiculopustular dermatosis ▪ Paraneoplastic pemphigus: paraneoplastic autoimmune multi-organ syndrome

Key features

- Pemphigus is a group of autoimmune blistering diseases of the skin and mucous membranes that is characterized by:
  - histologically, intraepidermal blisters due to the loss of cell–cell adhesion of keratinocytes
  - immunopathologically, the finding of *in vivo* bound and circulating IgG autoantibodies directed against the cell surface of keratinocytes
- Pemphigus is divided into three major forms: pemphigus vulgaris, pemphigus foliaceus, and paraneoplastic pemphigus
- The functional inhibition of desmogleins, which play an important role in cell–cell adhesion of keratinocytes, by IgG autoantibodies results in blister formation
- Patients with pemphigus vulgaris and pemphigus foliaceus have IgG autoantibodies against desmoglein 3 and desmoglein 1, respectively, while patients with paraneoplastic pemphigus also have IgG autoantibodies against plakin molecules as well as a T cell-mediated autoimmune reaction that leads to an interface dermatitis
- IgA pemphigus is characterized by IgA, but not IgG, autoantibodies directed against keratinocyte cell surfaces and is divided into two major subtypes: intraepidermal neutrophilic (IEN) type and subcorneal pustular dermatosis (SPD) type
- Systemic corticosteroids are a mainstay of therapy in pemphigus vulgaris, given the rapidity of clinical response, but because of their potential side effects at effective doses, they are combined with steroid-sparing agents
- These additional therapies include immunosuppressive medications such as mycophenolate mofetil, high-dose IVIg (non-immunosuppressive), and anti-CD20 monoclonal antibodies
- Rituximab represents a first-line, FDA-approved therapeutic option for moderate-to-severe pemphigus and can also benefit patients who do not achieve clinical remission with systemic corticosteroids and/or other adjuvant immunosuppressive drugs

INTRODUCTION

The term pemphigus stems from the Greek *pemphix*, meaning blister or bubble, and it describes a group of chronic blistering skin diseases in which autoantibodies are directed against the cell surface of keratinocytes, resulting in the loss of cell–cell adhesion of keratinocytes through a process called acantholysis[1]. Pemphigus can be divided into three major forms: pemphigus vulgaris, pemphigus foliaceus, and paraneoplastic pemphigus (Table 29.1).

Pemphigus vulgaris and pemphigus foliaceus are the originally characterized, classic forms of pemphigus[2]. All patients with pemphigus vulgaris have mucosal membrane erosions, and more than half will also have cutaneous blisters and erosions. The blisters of pemphigus vulgaris develop within the deeper portion of the epidermis, just above the basal cell layer. Patients with pemphigus foliaceus only have cutaneous involvement without mucosal lesions, and the splits occur in the superficial portion of the epidermis, mostly at the granular layer. Pemphigus vegetans is a variant of pemphigus vulgaris, and pemphigus erythematosus and fogo selvagem represent localized and endemic variants of pemphigus foliaceus, respectively.

Paraneoplastic pemphigus is distinct from the classic forms of pemphigus[3], as it consists of both humoral and cellular autoimmune reactions. Patients with paraneoplastic pemphigus have a known or occult associated neoplasm, usually of lymphoid tissue. Painful, severe oral and conjunctival erosions are a prominent feature of paraneoplastic pemphigus.

HISTORY

The modern history of pemphigus began with the discovery by Beutner and Jordon in 1964 of circulating antibodies directed against the cell surface of keratinocytes in the sera of pemphigus vulgaris patients[4] (Fig. 29.1). This was followed by the finding of *in vivo* IgG deposition on the cell surface of keratinocytes in patients' skin. These discoveries formed the basis of our understanding of pemphigus as a tissue-specific autoimmune disease of the skin and mucous membranes. In the late 1970s and early 1980s, pemphigus autoantibodies were shown to be pathogenic, i.e. they could induce blister formation in skin organ-culture systems as well as by passive transfer of patients' IgG to neonatal mice[5]. In the mid and late 1980s, the target antigens of pemphigus were characterized by immunochemical methods, such as immunoprecipitation and immunoblotting[6]. In the early 1990s, the isolation of cDNA for pemphigus antigens demonstrated that pemphigus is an anti-cadherin autoimmune disease[7].

EPIDEMIOLOGY

The prevalence of pemphigus vulgaris and pemphigus foliaceus in men and women is approximately equal. The mean age of onset of disease is 50 to 60 years, although the range is broad and disease arising in the elderly and in children has been described. Pemphigus can be found all over the world. Although limited data are available regarding the incidence of pemphigus, in general, it ranges from 0.76 to 5 new cases per million per year, with a higher incidence observed in the Middle East, Southeast Europe, and India. However, the incidence is much higher (16 to 32 cases per million per year) in those of Jewish ancestry, particularly Ashkenazi Jews. Occasionally, this ancestry may not be readily apparent, as in the descendants of the *conversos* (Jews from the Iberian peninsula who were forced to convert to Catholicism), who currently reside in the southwestern USA and Latin America.

In most countries, pemphigus vulgaris is more common than pemphigus foliaceus; exceptions include Finland, Tunisia, and Brazil. For example, in Japan (incidence of pemphigus: 3.5 cases per million per year), the ratio of pemphigus vulgaris to pemphigus foliaceus is 2 : 1. In France (incidence: 1.7 cases per million per year), pemphigus vulgaris accounts for the majority of all cases (~75%), as it does in Bulgaria. In contrast, in Finland (incidence: much lower at 0.76 cases per million per year) and in Tunisia (incidence: 6.7 cases per million per year), pemphigus foliaceus is twice as common as pemphigus vulgaris. More interestingly, the female-to-male ratio in Tunisia is 4 : 1, and the incidence is higher in young women ages 25 to 34 years (15.5 cases per million per year). In addition to Brazil, Tunisia may have endemic foci of pemphigus foliaceus as may the Mt. Kilimanjaro area.

Downloaded for Anonymous User (n/a) at Egyptian Knowledge Bank from ClinicalKey.com by Elsevier on March 10, 2024. For personal use only. No other uses without permission. Copyright ©2024. Elsevier Inc. All rights reserved.

CLASSIFICATION OF PEMPHIGUS

• Pemphigus vulgaris
  • Pemphigus vegetans
• Pemphigus foliaceus
  • Pemphigus erythematosus: localized
  • Fogo selvagem: endemic
• Herpetiform pemphigus
• Drug-induced pemphigus*
• Paraneoplastic pemphigus
• IgA pemphigus

*ACE inhibitors (e.g. captopril), penicillamine > gold, pyritinol, antibiotics (especially β-lactams), immune checkpoint inhibitors (e.g. pembrolizumab), nifedipine, phenobarbital, piroxicam, propranolol, pyrazolone and topical imiquimod.

Table 29.1 Classification of pemphigus.

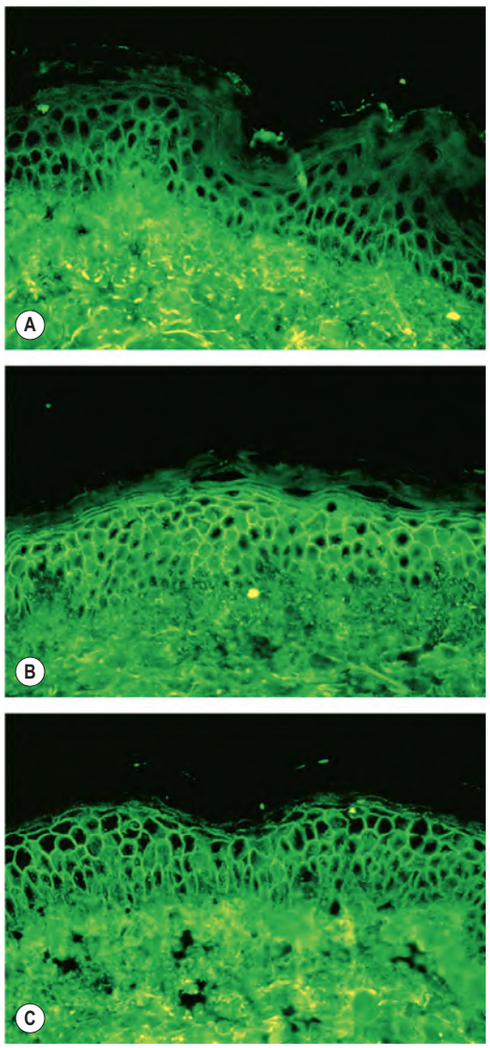

Fig. 29.1 Indirect immunofluorescence of pemphigus sera with normal human epidermis as a substrate. The hallmark of pemphigus is the finding of IgG autoantibodies directed against the cell surface of keratinocytes. **A** Pemphigus vulgaris sera containing anti-desmoglein 3 (anti-Dsg3) IgG alone stain predominantly the cell surfaces in the lower epidermis. **B** Pemphigus vulgaris sera containing both anti-Dsg3 IgG and anti-Dsg1 IgG stain the cell surfaces throughout the epidermis. **C** Pemphigus foliaceus sera, which contain only anti-Dsg1 IgG, stain the cell surfaces throughout the epidermis, but more intensely in the superficial layers.

Fogo Selvagem

Patients with fogo selvagem are clinically, histologically, and immunopathologically similar to patients with sporadic pemphigus foliaceus. However, fogo selvagem occurs in an endemic fashion in certain regions of Brazil and is thought to be caused by an environmental factor(s). Unlike sporadic pemphigus foliaceus, which is a disease of mostly middle-aged and older patients, fogo selvagem affects young adults and children of either sex or any race who are exposed to the local ecology in rural areas, and the incidence gradually decreases as the area is developed. The majority of patients live close to rivers and within the 10–15 km flying range of black flies (*Simulium* spp.), which may be the vector that precipitates the disease. There is also a high frequency of hematophagous insects (bedbugs and kissing bugs) in the homes of patients with fogo selvagem. Of note, a salivary protein from the sand fly *Lutzomyia longipalpis* was shown to induce cross-reactive antibodies to Dsg1[8].

Fogo selvagem frequently occurs in genetically related family members, although it is not contagious, and, to date, spread by blood products or body fluids has not been documented. In rural Brazil, the ratio of pemphigus foliaceus to pemphigus vulgaris is a remarkable 17:1. The prevalence in some rural areas of Brazil is as high as 3.4% of the population[9]. Furthermore, in these areas, more than 50% of normal individuals have anti-desmoglein 1 (anti-Dsg1) IgG autoantibodies, and it has been shown that the onset of the disease is preceded by a sustained antibody response consisting of non-pathogenic IgG1 and IgG4 antibodies. In certain genetically predisposed individuals, predominant IgG4 antibodies directed against the N-terminal extracellular EC1 and EC2 domains of Dsg1 are responsible for inducing disease (Fig. 29.2)[10]. Certainly, fogo selvagem provides a fascinating model for understanding the pathophysiologic and immunologic mechanisms involved in triggering an autoimmune response against skin components.

PATHOGENESIS

Pathogenic Autoantibodies in Pemphigus

The hallmark of pemphigus is the finding of IgG autoantibodies against the cell surface of keratinocytes (see Fig. 29.1)[4]. The pemphigus autoantibodies found in patients' sera play a primary pathogenic role in inducing the loss of cell adhesions between keratinocytes, and subsequent blister formation. Neonates of mothers with pemphigus vulgaris may have a transient disease caused by maternal IgG that crosses the placenta.[11] As maternal antibody is catabolized, the disease subsides. IgG fractions from patients can induce blister formation in the absence of complement or inflammatory cells in a skin organ-culture system[5]. Furthermore, passive transfer of patients' IgG to neonatal mice results in blisters in the mice with typical histologic findings[5]. Even monovalent Fab′ fragments of IgG from patients with pemphigus foliaceus are sufficient to cause blisters in neonatal mice, indicating complement activation and surface cross-linking may not be essential in keratinocyte detachment[12].

Desmogleins as Pemphigus Antigens

Immunoelectron microscopy localized both pemphigus vulgaris and pemphigus foliaceus antigens to the desmosomes, the most prominent cell–cell adhesion junctions in stratified squamous epithelia[13]. Immunochemical characterization of pemphigus antigens by immunoprecipitation or immunoblotting with extracts from cultured keratinocytes or epidermis demonstrated that the pemphigus vulgaris and foliaceus antigens were 130 kDa and 160 kDa transmembrane glycoproteins, respectively (Table 29.2)[7,14]. By comparative immunochemical studies using anti-desmoglein 1 (Dsg1) monoclonal and polyclonal antibodies, the 160 kDa protein recognized by pemphigus foliaceus sera was subsequently shown to be identical to Dsg1. An 85 kDa plaque protein, plakoglobin, was co-immunoprecipitated with the 130 kDa and 160 kDa pemphigus antigens, demonstrating that plakoglobin forms a molecular complex with pemphigus vulgaris and foliaceus antigens[15].

Molecular cloning of cDNA encoding Dsg1 and pemphigus vulgaris antigens indicated that both molecules were members of the cadherin supergene family[7,16]. Thus, pemphigus was discovered to be an anti-cadherin autoimmune disease. The pemphigus vulgaris antigen was termed desmoglein 3 (Dsg3). The basic pathophysiology of pemphigus is as follows: autoantibodies inhibit the adhesive function of desmogleins and lead to the loss of the cell–cell adhesion of keratinocytes, resulting in blister formation.

Cadherins are a family of calcium-dependent cell–cell adhesion molecules that play an important role in the formation and maintenance of complex tissue integrity[17]. Based on sequence similarity, cadherins have two major subgroups: *classic* cadherins (e.g. E-, P-, N-cadherins) and *desmosomal* cadherins (desmogleins and desmocollins). All members of the cadherin family contain conserved repeated amino acid sequences (cadherin repeats) with calcium-binding motifs in their extracellular domains (see Fig. 29.2). When classic cadherins were introduced by gene transfection into non-adhesive mouse fibroblast L cells, the cells acquired strong cell adhesion activity mediated by a homophilic type of

Downloaded for Anonymous User (n/a) at Egyptian Knowledge Bank from ClinicalKey.com by Elsevier on March 10, 2024. For personal use only. No other uses without permission. Copyright ©2024. Elsevier Inc. All rights reserved.

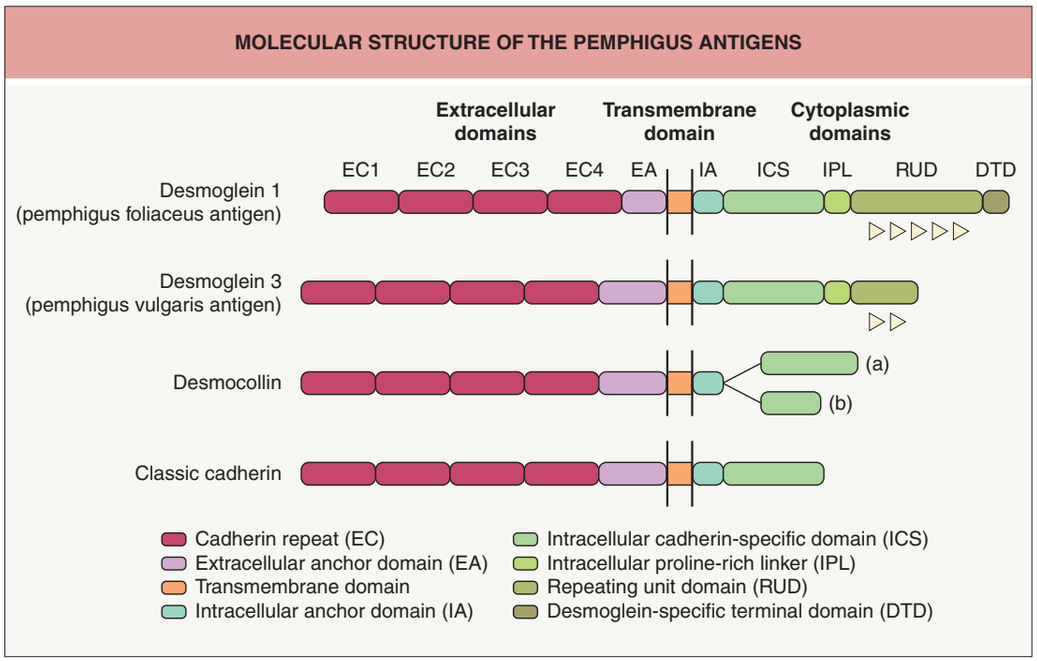

Fig. 29.2 Molecular structure of the pemphigus antigens. The extracellular (EC) region has four cadherin repeats, which have calcium-binding motifs. The intracellular cadherin-specific (ICS) domain is well conserved among cadherins and it is responsible for interactions with β-catenin or plakoglobin (see Fig. 29.3). Desmogleins have their own unique sequences (repeating unit domain [RUD]) of repeats of 29 ± 1 residues (arrowheads). Each desmocollin isotype has two products (a and b) derived from alternatively spliced transcripts of a single gene.

TARGET ANTIGENS IN PEMPHIGUS

Disease	Autoantibodies	Antigens	MW (kDa)
Pemphigus vulgaris			
Mucosal-dominant type	IgG	Desmoglein 3	130
Mucocutaneous type	IgG	Desmoglein 3	130
		Desmoglein 1	160
Pemphigus foliaceus	IgG	Desmoglein 1	160
Paraneoplastic pemphigus	IgG	Desmoglein 3	130
		Desmoglein 1	160
		Plectin*	500
		Epiplakin*	500
		Desmoplakin I*	250
		Desmoplakin II*	210
		BPAG1*	230
		Envoplakin*	210
		Periplakin*	190
		A2ML1	170
		Transglutaminase 1	90
Drug-induced pemphigus	IgG	Desmoglein 3	130
		Desmoglein 1	160
IgA pemphigus			
Subcorneal pustular dermatosis type	IgA	Desmocollin 1	110/100
Intraepidermal neutrophilic type	IgA	?	?
Pemphigus foliaceus type	IgA	Desmoglein 1	160
Pemphigus vulgaris type	IgA	Desmoglein 3	130
Pemphigus vegetans type	IgA	Desmoglein 3	130

*Members of plakin family.

Table 29.2 Target antigens in pemphigus. A minority of patients with classic pemphigus vulgaris and pemphigus foliaceus also have IgA autoantibodies and are classified as pemphigus vulgaris and pemphigus foliaceus. A2ML1, alpha-2-macroglobulin-like-1 protease inhibitor; BPAG1, bullous pemphigoid antigen 1.

interaction. Cadherins require their well-conserved cytoplasmic domains in order to associate with the plaque proteins, α-catenin, β-catenin and plakoglobin, which mediate and regulate binding to the cytoskeleton network (Fig. 29.3). As a consequence of these interactions, cadherins produce strong cellular adhesion and morphologic changes in the cells. Cadherin molecules form dimers as their functional unit, with the distal extracellular domain (EC1) of the cadherin from one cell binding to the same region of a second cadherin from an opposing cell[18].

Two major types of adhering junctions of epithelial cells are commonly distinguished: adherens junctions and desmosomes (see Fig. 29.3). The *adherens junction* anchors bundles of actin microfilaments and contains classic cadherins as its transmembrane components and α-catenin, β-catenin, and plakoglobin as its cytoplasmic components. In contrast, the *desmosome* anchors intermediate filaments like keratins and contains desmosomal cadherins as its transmembrane components and plakoglobin, plakophilin, and desmoplakin

Downloaded for Anonymous User (n/a) at Egyptian Knowledge Bank from ClinicalKey.com by Elsevier on March 10, 2024. For personal use only. No other uses without permission. Copyright ©2024. Elsevier Inc. All rights reserved.

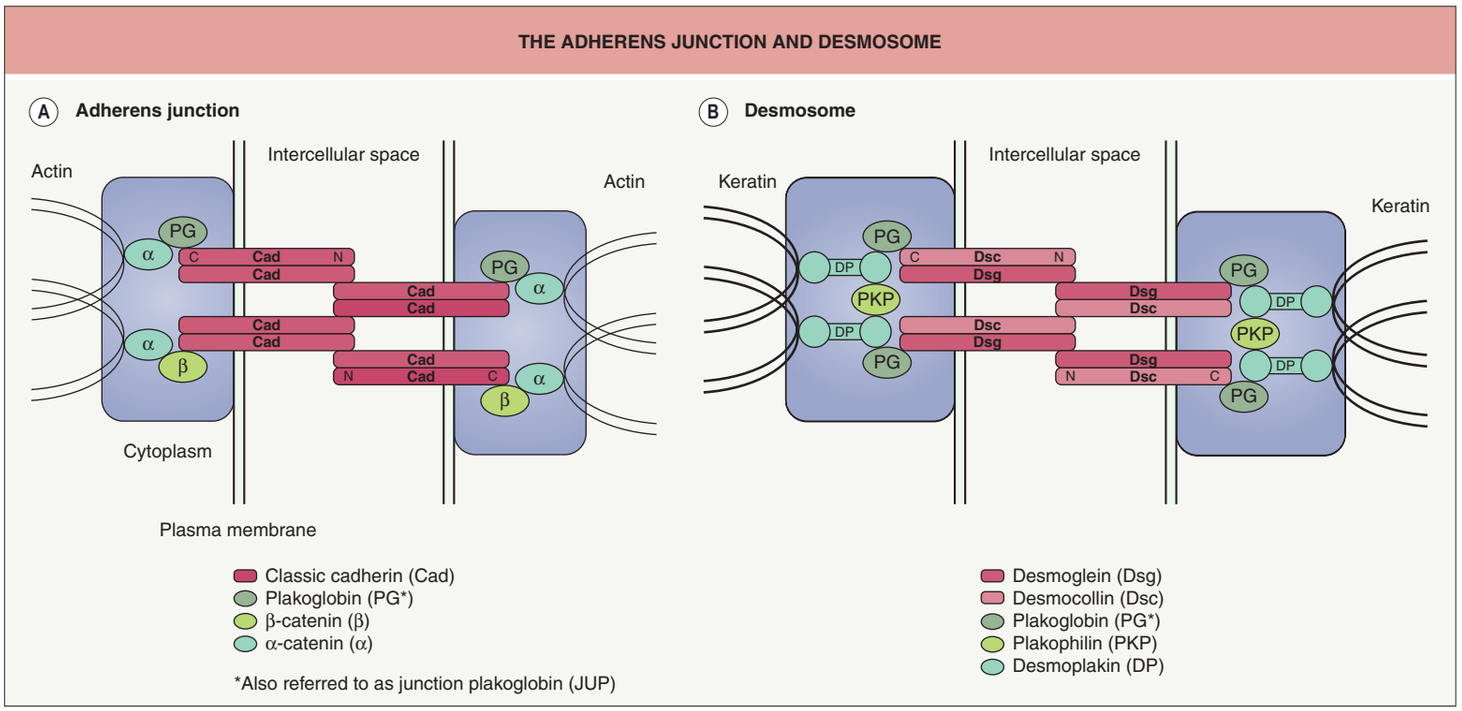

Fig. 29.3 The adherens junction and desmosome. A The adherens junction complex contains classic cadherins as transmembrane constituents and α-catenins, β-catenins, and plakoglobin as cytoplasmic constituents. A classic cadherin is directly coupled through its cytoplasmic tail to β-catenin or plakoglobin, which in turn is linked to α-catenin, which binds to actin. **B** The desmosome complex includes desmogleins and desmocollins as transmembrane constituents, and plakoglobin, plakophilin, and desmoplakin as cytoplasmic constituents. Desmogleins and desmocollins form heterodimers as a functional adhesive unit and associate with plakoglobin, which in turn binds to desmoplakin which links keratin to the membrane. C, carboxy terminus; N, amino terminus.

as its cytoplasmic components. In general, adherens junctions mediate quick but weak cellular adhesion, whereas desmosomes mediate slow but strong cellular adhesion.

Desmogleins have four cadherin repeats in their extracellular domain, as do classic cadherins (see Fig. 29.2). Desmogleins have four isoforms (Dsg1–4). Expression of Dsg1 and Dsg3 is basically restricted to stratified squamous epithelia, where blisters are formed in pemphigus, while Dsg2 is expressed in all desmosome-possessing tissues, including simple epithelia and myocardium. Dsg4 plays an important adhesive role primarily in hair follicles, and mutations in *DSG4* can lead to abnormal hair development (e.g. localized autosomal recessive hypotrichosis)[19].

Desmocollins are another group of transmembrane glycoproteins within desmosomes and they have three isoforms (Dsc1–3). Each isoform has two products derived from alternatively spliced mRNA of a single gene. Desmosomes always have desmoglein and desmocollin as a pair, with Dsg:Dsc heterodimers representing the fundamental adhesive unit of desmosomes and thus providing a structural framework for understanding desmosome assembly[20].

Plakoglobin and plakophilin, together with β-catenin, are members of the armadillo family of nuclear and junctional proteins, which are not only simple anchoring molecules but also dynamic regulators of cellular adhesion and proliferation. Desmoplakin is a dumbbell-shaped molecule composed of three domains: a central α-helical coiled-coil rod, flanked by globular carboxy- and amino-terminal domains that interact with intermediate filaments and armadillo family members, respectively (see Fig. 29.3). Desmoplakin has two products derived from alternatively spliced mRNA of a single gene: desmoplakin I (250 kDa) and II (210 kDa) (see Table 29.2). Desmoplakin, a member of the plakin family, plays an important role in the anchorage of the cytoskeleton to filament attachment sites on desmosomes.

Compelling evidence has accumulated that IgG autoantibodies against Dsg1 and Dsg3 are pathogenic and play a primary role in inducing the blister formation in pemphigus. Essentially, all patients with pemphigus have IgG autoantibodies against Dsg1 and/or Dsg3, depending on the subtype of pemphigus[21,22]. When anti-desmoglein IgG autoantibodies are removed from the sera of patients with pemphigus vulgaris, pemphigus foliaceus or paraneoplastic pemphigus (by immunoadsorption with recombinant desmoglein proteins), the sera are no longer pathogenic in inducing blister formation[23,24]. Furthermore, anti-desmoglein IgG autoantibodies that have been affinity-purified from pemphigus sera via desmoglein recombinant proteins can cause blisters when injected into neonatal mice[24,25]. Some pemphigus sera react with Dsg4 due to cross-reactivity of a subset of anti-Dsg1 IgG, although Dsg4/Dsg1-cross-reacting IgG has no demonstrable pathogenic effect[26]. IgG autoantibodies against non-desmoglein molecules, such as acetylcholine receptors or annexin-like molecules, have also been detected, but their pathogenic relevance in pemphigus remains to be determined.

Desmoglein Compensation Theory as Explanation for Localization of Blisters

The sites of blisters in pemphigus vulgaris and foliaceus are explained logically by the desmoglein compensation theory: Dsg1 and Dsg3 compensate for each other when they are coexpressed in the same cell (Fig. 29.4)[27,28]. While patients with pemphigus foliaceus have only anti-Dsg1 IgG autoantibodies, individuals with the mucosal-dominant type of pemphigus vulgaris have only anti-Dsg3 IgG autoantibodies. Those with the mucocutaneous type of pemphigus vulgaris have both anti-Dsg3 and anti-Dsg1 IgG autoantibodies. Of note, the intraepithelial expression pattern of Dsg1 and Dsg3 differs between the skin and mucous membranes. In the skin, Dsg1 is expressed throughout the epidermis, but more intensely in the superficial layers (see Fig. 29.1C), whereas Dsg3 is expressed in the lower portion of the epidermis, primarily in the basal and parabasal layers (see Fig. 29.1A). In contrast to the skin, Dsg1 and Dsg3 are expressed throughout the squamous layer of mucosa, but Dsg1 is expressed at a much lower level than Dsg3 (see Fig. 29.4B).

When sera contain only anti-Dsg1 IgG (which interferes with the function of Dsg1), blisters appear only in the superficial epidermis of the skin because that is the only area in which Dsg1 is present without coexpression of Dsg3. The splits occur between the second (SG2) and the third (SG3) layers of the stratum granulosum (SG) because IgG does not go beyond the tight junctions present between SG2 cells[29]. In the unaffected deep epidermis, the presence of Dsg3 compensates for the loss of function of Dsg1. Although the anti-Dsg1 IgG binds to mucosa, no blisters are formed, because of the coexpression of Dsg3.

Downloaded for Anonymous User (n/a) at Egyptian Knowledge Bank from ClinicalKey.com by Elsevier on March 10, 2024. For personal use only. No other uses without permission. Copyright ©2024. Elsevier Inc. All rights reserved.

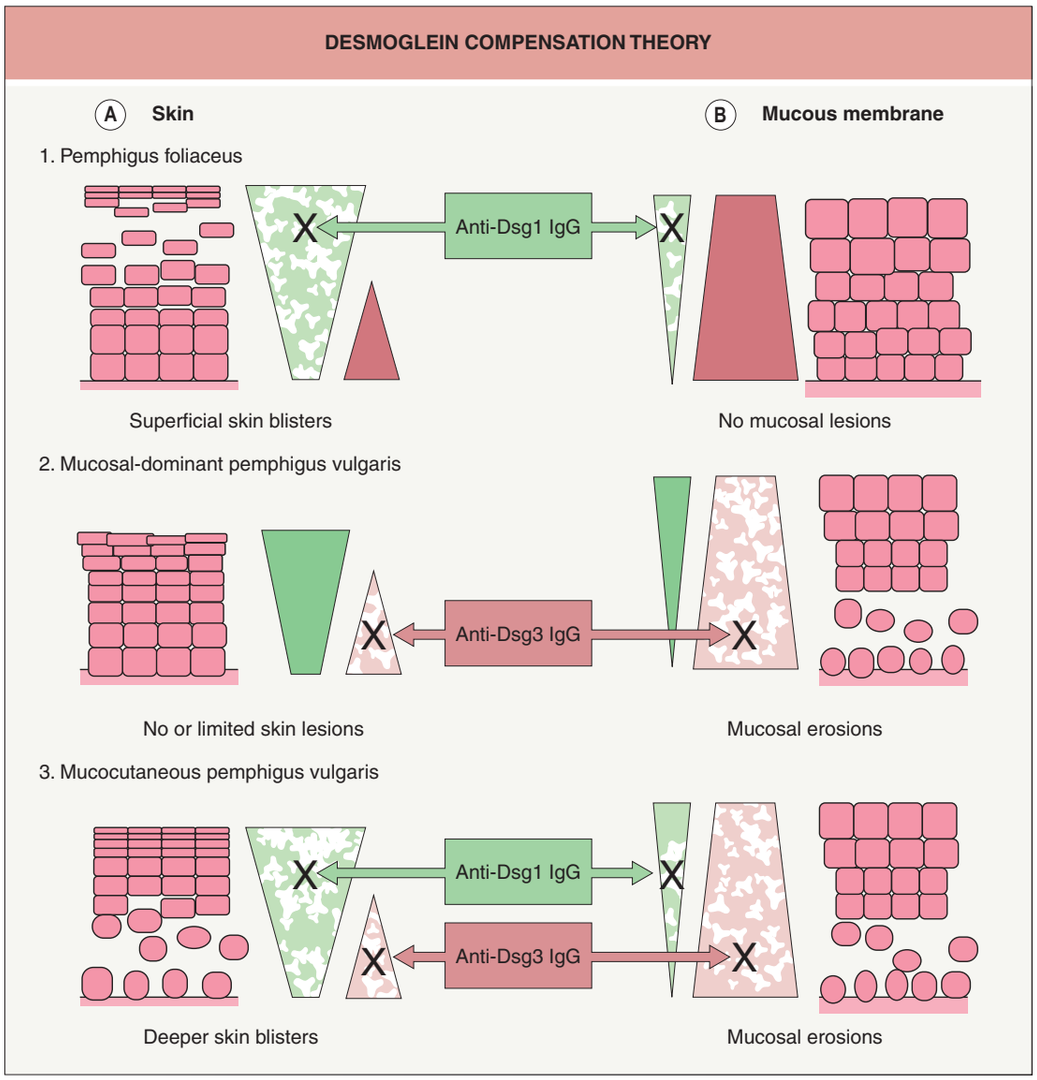

Fig. 29.4 Logical explanation for the localization of blister formation in classic pemphigus by desmoglein compensation theory. The colored triangles represent the distribution of desmoglein 1 (Dsg1, green) and desmoglein 3 (Dsg3, pink) in the skin (**A**) and mucous membranes (**B**). Pemphigus foliaceus sera contain only anti-Dsg1 IgG, which causes superficial blisters in the skin because Dsg3 functionally compensates for the impaired Dsg1 in the lower part of the epidermis (A1), whereas those antibodies do not cause blisters in the mucous membranes because cell–cell adhesion is mainly mediated by Dsg3 (B1). Sera containing only anti-Dsg3 IgG cause no or only limited blisters in the skin because Dsg1 compensates for the loss of Dsg3-mediated adhesion (A2); however, these sera induce separation in the mucous membranes, where the low expression of Dsg1 will not compensate for the loss of Dsg3-mediated adhesion (B2). When sera contain both anti-Dsg1 and anti-Dsg3 IgG, the function of both Dsgs is compromised and blisters occur in both the skin and mucous membranes (A3, B3). In neonatal skin, the situation is similar to that shown here for mucous membranes.

Thus, sera containing only anti-Dsg1 IgG cause superficial blisters in the skin without mucosal involvement, as is seen in patients with pemphigus foliaceus (see Fig. 29.4).

When sera contain only anti-Dsg3 IgG, they are inefficient in producing cutaneous blisters because coexpressed Dsg1 compensates for the impaired function of Dsg3, resulting in no, or only limited, skin lesions. However, in the mucous membranes, Dsg1 cannot compensate for the impaired Dsg3 function because of its low expression. Therefore, sera containing only anti-Dsg3 IgG cause oral erosions without apparent skin involvement, as is seen in patients with the mucosal-dominant type of pemphigus vulgaris (see Fig. 29.4).

When sera contain both anti-Dsg1 and anti-Dsg3 IgG, they interfere with the function of both Dsg1 and Dsg3, resulting in extensive blisters and erosions of the skin as well as the mucous membranes, as is seen in patients with the mucocutaneous type of pemphigus vulgaris. Possible explanations for why splits appear just above the basal layer, rather than the whole epithelium falling apart, include: (1) cell–cell adhesion in the basal and parabasal layers may be weaker than in other parts of the epithelium; and (2) autoantibodies, which penetrate from the dermis, might have better access to the lower part of the epithelia.

In pregnant women with pemphigus, autoantibodies cross the placenta and bind to the fetal epidermis. However, neonates develop blisters if the mother has pemphigus vulgaris, but very rarely if she has pemphigus foliaceus. This confusing observation is also explained by the desmoglein compensation theory[30]. The distribution of Dsg3 within neonatal epidermis is unlike that in adult epidermis; it is found on the surface of keratinocytes throughout the epidermis, which is similar to its distribution in mucous membranes (remember, neonatal skin is bathed in amniotic fluid). Therefore, pemphigus foliaceus sera containing only anti-Dsg1 IgG cannot efficiently induce blisters in neonatal skin.

As an extension of this compensation theory, exfoliative toxins, which are produced by *Staphylococcus aureus* and lead to bullous impetigo as well as staphylococcal scalded skin syndrome, specifically cleave Dsg1[31]. Inactivation of Dsg1 by this toxin induces superficial blisters in the epidermis that are clinically and histologically similar to those seen in pemphigus foliaceus.

In pemphigus, the disruption of cell–cell adhesion is currently thought to be mediated via the combined effects of direct inhibition by antibodies plus subsequent signal transduction induced by antibody binding[32]. The direct inhibition is mediated by steric hindrance, i.e. the binding of autoantibodies to desmogleins spatially interferes with the adhesive interaction of desmogleins between cells. This proposed pathogenesis is supported by the following observations: (1) in pemphigus vulgaris and foliaceus, dominant epitopes are localized to the functionally important N-terminal regions of desmogleins[25,33]; and (2) pathogenic anti-Dsg3 mouse or human monoclonal antibody, but *not* non-pathogenic monoclonal antibodies, recognizes the N-terminal adhesive surface of Dsg3 (see Fig. 29.3B)[33,34]. The phenotype of the *Dsg3* null mouse (whose *Dsg3* gene is genetically deleted) closely resembles that of human pemphigus vulgaris patients[35]. The role of signal transduction induced by antibody binding is supported by the *in vitro* observation that IgG from pemphigus vulgaris sera (when added to the media of cultured keratinocytes) causes a transient increase in intracellular calcium and/or inositol 1,4,5-triphosphate, activation of protein kinase C, or phosphorylation of Dsg3. Furthermore, with desmosomal disassembly, Dsg3 is internalized or endocytosed from the cell surface in association with keratin retraction[36].

Downloaded for Anonymous User (n/a) at Egyptian Knowledge Bank from ClinicalKey.com by Elsevier on March 10, 2024. For personal use only. No other uses without permission. Copyright ©2024. Elsevier Inc. All rights reserved.

Humoral and Cellular Autoimmunity in Paraneoplastic Pemphigus

Patients with paraneoplastic pemphigus develop characteristic IgG autoantibodies against multiple antigens[3], including Dsg3 and/or Dsg1[24], multiple members of the plakin family (plectin, epiplakin, desmoplakins I and II, bullous pemphigoid antigen 1, envoplakin, and periplakin), the protease inhibitor alpha-2-macroglobulin-like-1[37,38], and transglutaminase 1[38a] (see Table 29.2). Anti-desmoglein antibodies play a role in inducing the loss of cell adhesion of keratinocytes and initiate blister formation, while the pathophysiologic relevance of the anti-plakin autoantibodies is unclear, in that plakin molecules are intracellular and IgG cannot penetrate cell membranes. In addition to humoral autoimmunity, cell-mediated cytotoxicity is involved in the pathogenesis of paraneoplastic pemphigus, in which more severe and refractory oral erosions and stomatitis as well as more polymorphic skin eruptions are seen, in comparison with classic forms of pemphigus. It was demonstrated in mice that Dsg3-specific T cells not only help B cells produce anti-Dsg3 IgG (which causes acantholysis), but also directly infiltrate into the epidermis and induce an interface dermatitis[39]. Clarification of the exact roles of autoimmune T cells should provide valuable insights into the pathophysiology of paraneoplastic pemphigus.

Immunologic Mechanism of Pathogenic Autoantibody Production in Pemphigus

In contrast to the significant progress since the late 1980s in understanding the pathophysiologic mechanisms of blister formation in pemphigus, it is still unclear why patients with pemphigus begin to produce the pathogenic autoantibodies.

Pemphigus autoantibodies are composed of IgG isotypes, which may be produced after isotype switching, and they have a high affinity towards the antigen, which may be a result of affinity maturation of the antibodies. In addition, pemphigus sera recognize several distinct epitopes on desmogleins[40], and the presence of autoantibodies is associated with specific HLA class II alleles, including DRB1*0402, DRB1*1401, and DQB1*0302 in White individuals[41] and DRB1*14 and DQB1*0503 in Japanese. All of these features suggest that autoantibody production in pemphigus is T cell-dependent. More recently, T cells reactive against Dsg3 were shown to be present in peripheral blood from patients with pemphigus vulgaris as well as healthy individuals[42–44]. Certain peptides from Dsg3, predicted to fit into the DRB1*0402 pocket, were able to stimulate T cells from the pemphigus patients.

Another advance that will allow the study of T cells and B cells is the development of an active disease mouse model for pemphigus vulgaris[45]. This model is valuable not only for dissecting the cellular and molecular mechanisms involved in antibody production but also for developing novel therapeutic strategies.

CLINICAL FEATURES

Pemphigus Vulgaris

Essentially all patients with pemphigus vulgaris develop painful erosions of the oral mucosa. More than half of the patients also develop flaccid blisters and widespread cutaneous erosions. Pemphigus vulgaris is therefore divided into two subgroups: (1) the *mucosal-dominant* type with mucosal erosions but minimal skin involvement; and (2) the *mucocutaneous* type with extensive skin blisters and erosions in addition to mucosal involvement (see Fig. 29.4).

Mucous membrane lesions usually present as painful erosions (Fig. 29.5). Intact blisters are rare, probably because they are fragile and break easily. Although scattered or extensive erosions may be seen anywhere in the oral cavity, the most common sites are the buccal and palatine mucosae. The erosions are of different sizes with an irregular and ill-defined border, which, when extensive or painful, may result in decreased oral intake of food or liquids. The diagnosis of pemphigus vulgaris tends to be delayed in patients presenting with only oral involvement, as compared to patients with skin lesions.

The lesions may extend out onto the vermilion lip and lead to thick, fissured hemorrhagic crusts. Involvement of the throat produces hoarseness and difficulty in swallowing. The esophagus also may be involved and sloughing of its entire lining in the form of a cast has been reported. The conjunctivae, nasal mucosa, vagina, labia, penis and anus can develop lesions as well. Cytology of vaginal cells may be misread as a malignancy when vaginal lesions are present.

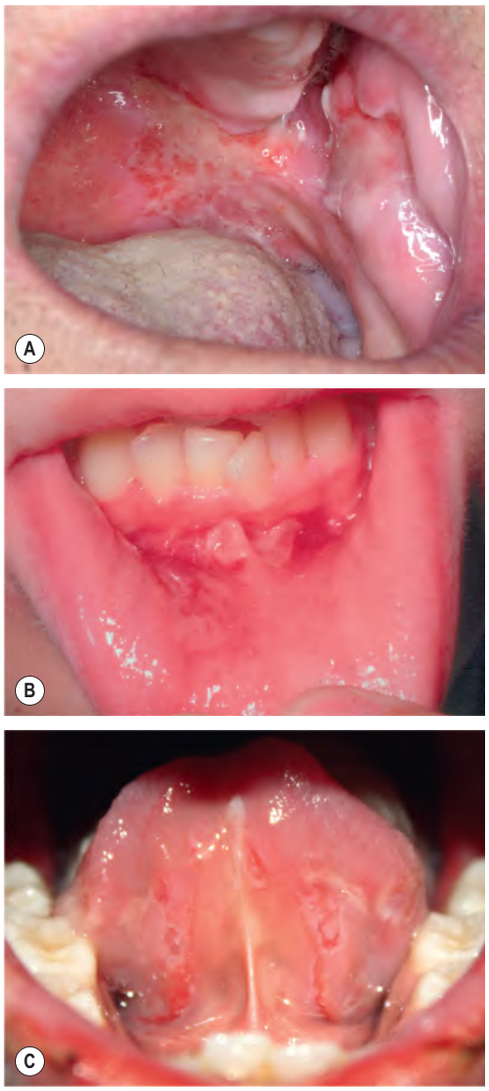

Fig. 29.5 Pemphigus vulgaris – oral involvement. Essentially all patients develop painful oral mucosal erosions. The most common sites are the buccal (**A**) and palatine mucosae, but lesions can also develop on the gingivae (**B**) and tongue (**C**). *A, Courtesy Lorenzo Cerroni, MD; B,C, Courtesy Jeffrey P. Callen, MD.*

The primary skin lesions of pemphigus vulgaris are flaccid, thin-walled, easily ruptured blisters (Fig. 29.6). They can appear anywhere on the skin surface and arise on either normal-appearing skin or erythematous bases. The fluid within the bullae is initially clear but may become hemorrhagic, turbid, or even seropurulent. The blisters are fragile and soon rupture to form painful erosions that ooze and bleed easily. These erosions often attain a large size and can become generalized. The erosions soon become partially covered with crusts that have little or no tendency to heal. Those lesions that do heal often leave hyperpigmented patches with no scarring. Associated pruritus is uncommon. Table 29.3 outlines more unusual clinical presentations of pemphigus vulgaris.

Because of an absence of cohesion within the epidermis, its upper layers easily move laterally with slight pressure or rubbing in patients with active disease (Nikolsky sign). The lack of cohesion of the skin may also be demonstrated with the "bulla-spread phenomenon" – gentle pressure on an intact bulla forces the fluid to spread under the skin away from the site of pressure (Asboe–Hansen sign, also referred to as the "indirect Nikolsky" or "Nikolsky II" sign). Without appropriate treatment, pemphigus vulgaris can be fatal because a large portion of the skin loses its epidermal barrier function, leading to the loss of body fluids or to secondary bacterial infections.

Pemphigus Vegetans

Pemphigus vegetans is a rare vegetative variant of pemphigus vulgaris, and it is thought to represent a reactive pattern of the skin to the autoimmune insult of pemphigus vulgaris.

Downloaded for Anonymous User (n/a) at Egyptian Knowledge Bank from ClinicalKey.com by Elsevier on March 10, 2024. For personal use only. No other uses without permission. Copyright ©2024. Elsevier Inc. All rights reserved.

Fig. 29.6 Pemphigus vulgaris – cutaneous involvement. A Flaccid blisters and an erosion due to rupture of a bulla. **B**, **C** Multiple erosions and hemorrhagic crusts of the back that can become extensive. Secondary bacterial infections are a potential complication. **D** A vegetative response can occasionally be seen in chronic recalcitrant lesions; the patient has a Cushingoid appearance due to use of chronic systemic corticosteroids. **E** The dyshidrosiform variant is uncommon. *A, D, Courtesy Luis Requena, MD; B, C, Courtesy Lorenzo Cerroni, MD; E, Courtesy Louis A. Fragola, Jr, MD.*

UNUSUAL CLINICAL PRESENTATIONS OF PEMPHIGUS VULGARIS
• Isolated crusted plaque on face or scalp
• Paronychia and/or onychomadesis
• Foot ulcers
• Dyshidrotic eczema or pompholyx
• Macroglossia
• Gingival hyperplasia

Table 29.3 Unusual clinical presentations of pemphigus vulgaris.

Fig. 29.7 Pemphigus vegetans. Large, thick, vegetating, papillomatous plaques arising in conjunction with erosions. Healed lesions have residual postinflammatory hyperpigmentation.

Pemphigus vegetans is characterized by flaccid blisters that become erosions and then form fungoid vegetations or papillomatous proliferations, especially in intertriginous areas and on the scalp or face (Fig. 29.7). Pustules rather than vesicles characterize early lesions, but these soon progress to vegetative plaques. The tongue may show cerebriform-like changes. Two subtypes are recognized: the severe Neumann type and the mild Hallopeau type. Occasionally, a vegetative response may also be seen in lesions of pemphigus vulgaris that tend to be resistant to therapy and remain for long periods of time in one location (see Fig. 29.6D).

Pemphigus Foliaceus

Patients with pemphigus foliaceus develop scaly, crusted cutaneous erosions, often on an erythematous base, but they do not have clinically apparent mucosal involvement even with widespread disease.

Downloaded for Anonymous User (n/a) at Egyptian Knowledge Bank from ClinicalKey.com by Elsevier on March 10, 2024. For personal use only. No other uses without permission. Copyright ©2024. Elsevier Inc. All rights reserved.

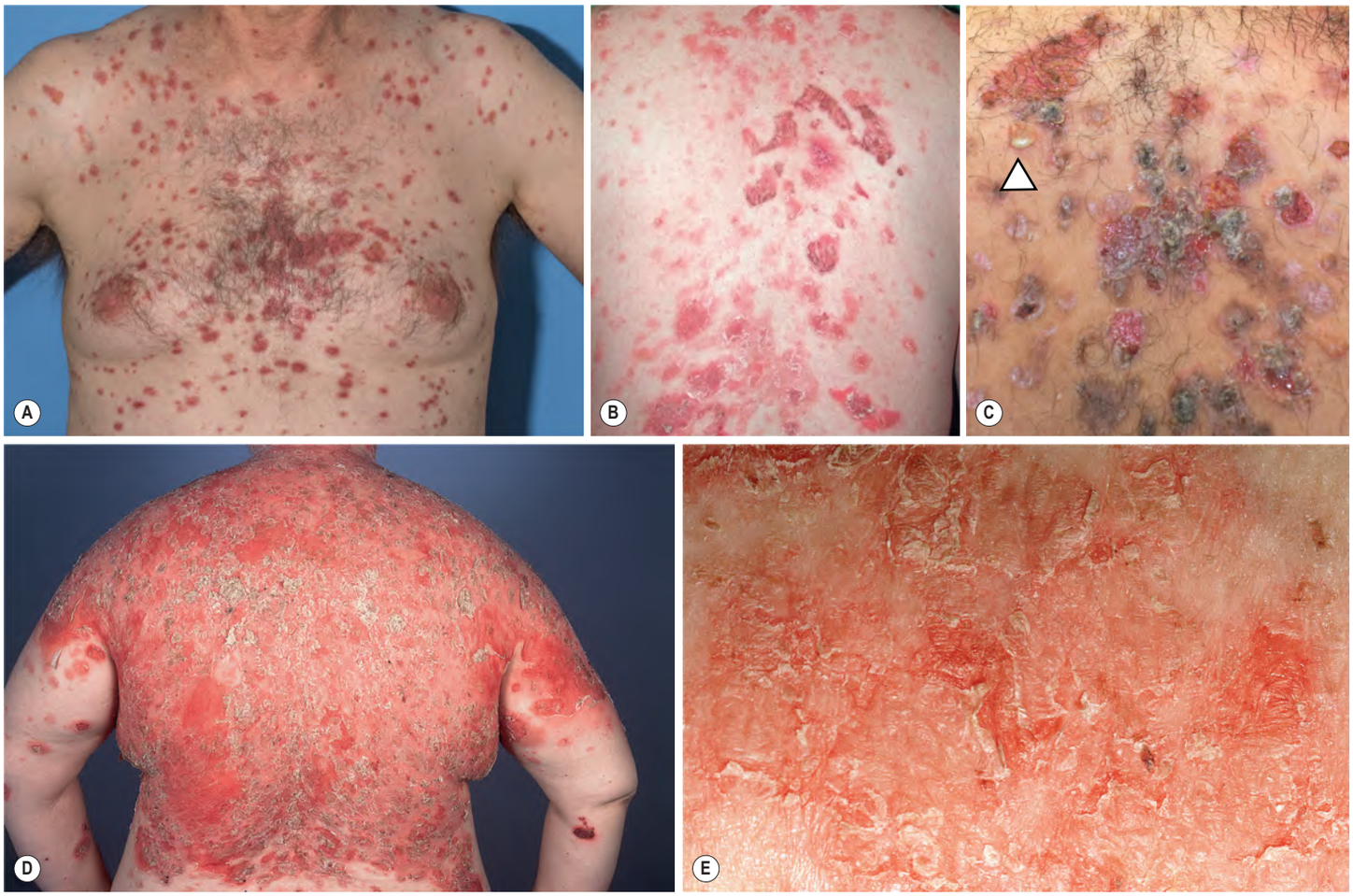

Fig. 29.8 Pemphigus foliaceus. A, B Multiple superficial erosions arising on an erythematous base on the trunk, a common site of involvement. Larger erosions as well as the characteristic scale-crusts are seen in **B**. **C** Thicker scale-crusts in addition to large erosions and one flaccid vesicle with seropurulent fluid where pus has settled in the lower half due to gravity similar to hypopyon ("half-half" blisters) (arrowhead). **D** As the disease progresses, the lesions become confluent, but because the vesicles are fragile and rupture easily, only erosions with scale-crust are observed. **E** The scales have been likened to cornflakes. *A, Courtesy Edward Cowen, MD; C, Courtesy Kalman Watsky, MD.*

The onset of disease is often subtle, with a few scattered crusted lesions that are transient and are frequently mistaken for impetigo. They are usually well demarcated and have a seborrheic distribution, i.e. they favor the face, scalp, and upper trunk (Fig. 29.8A–C). Because the vesicle is so superficial and fragile, often only the resultant crust and scale are seen (Fig. 29.8D, E). The disease may stay localized for years or it may rapidly progress, in some cases to generalized involvement and an exfoliative erythroderma (see Ch. 10). The Nikolsky sign is present. In contrast to the extensive oral lesions in pemphigus vulgaris, it is extremely rare, if ever, for patients with pemphigus foliaceus to develop mucosal involvement. Generally, patients with pemphigus foliaceus are not severely ill. However, they can experience burning and pain in association with the skin lesions.

Pemphigus Erythematosus (Senear–Usher Syndrome)

Pemphigus erythematosus is simply a localized variant of pemphigus foliaceus. Typical scaly and crusted lesions of pemphigus foliaceus appear in the malar region of the face (Fig. 29.9) and in other "seborrheic" areas. Originally, the term "pemphigus erythematosus" was introduced to describe patients with immunologic features of both lupus erythematosus (LE) and pemphigus, i.e. *in vivo* IgG and C3 deposition on cell surfaces of keratinocytes as well as the basement membrane zone, in addition to circulating anti-nuclear antibodies[46]. However, only a few patients have been reported to actually have the two diseases concurrently.

Fig. 29.9 Pemphigus erythematosus. Erythematous plaques with scale-crust and erosions on the nose and malar area of the face. *Courtesy Ronald P. Rapini, MD.*

Herpetiform Pemphigus

Most patients with herpetiform pemphigus have a clinical variant of pemphigus foliaceus and the remainder may have a variant of pemphigus vulgaris. This disorder is characterized by: (1) erythematous urticarial plaques and tense vesicles that present in a herpetiform arrangement; (2) eosinophilic spongiosis and subcorneal pustules with minimal or no apparent acantholysis histologically; and (3) IgG autoantibodies directed against the cell surfaces of keratinocytes[47]. The target antigen is Dsg1 in most cases and Dsg3 in the remainder[48]. Some patients with herpetiform pemphigus will have features of pemphigus foliaceus or vulgaris during the course of their disease, and some patients will evolve into having pemphigus foliaceus or vulgaris. It is assumed that the pathogenic blister-inducing activity of the IgG autoantibodies

Downloaded for Anonymous User (n/a) at Egyptian Knowledge Bank from ClinicalKey.com by Elsevier on March 10, 2024. For personal use only. No other uses without permission. Copyright ©2024. Elsevier Inc. All rights reserved.

in herpetiform pemphigus might be weaker than that seen in classic forms of pemphigus. Although often clinically less severe than pemphigus vulgaris, the course may be more chronic.

Drug-Induced Pemphigus

There are sporadic cases of pemphigus associated with the use of drugs, in particular penicillamine and captopril (see Table 29.1)[49]. In patients receiving penicillamine, pemphigus foliaceus is seen more commonly than pemphigus vulgaris, with a ratio of approximately 4:1. Although most patients with drug-induced pemphigus are shown to have autoantibodies against the same molecules involved in sporadic pemphigus, evidence suggests that some drugs may induce acantholysis without the production of antibodies. Both penicillamine and captopril contain sulfhydryl groups that are speculated to interact with the sulfhydryl groups in Dsg1 and Dsg3. This interaction may modify the antigenicity of the desmogleins, which may lead to autoantibody production, or their interaction may directly interfere with the adhesive function of the desmogleins. Imiquimod-induced pemphigus has also been reported as has a flare or recurrence of pemphigus due to immune checkpoint inhibitors. Most, but not all, patients with drug-induced pemphigus go into remission after the offending drug is discontinued.

Paraneoplastic Pemphigus

Paraneoplastic pemphigus is associated with underlying neoplasms, both malignant and benign. The most commonly associated neoplasms are non-Hodgkin lymphoma and chronic lymphocytic leukemia, followed by Castleman disease, malignant and benign thymomas, sarcomas, and Waldenström macroglobulinemia[3]. Non-Hodgkin lymphoma and chronic lymphocytic leukemia together account for two-thirds of patients. Castleman disease, a very rare lymphoproliferative disorder, is the third most commonly associated neoplasm in adults and the most commonly associated tumor in children and adolescents; its association with paraneoplastic pemphigus is strikingly disproportionate to its general occurrence. The absence of common tumors, such as adenocarcinomas of the breast or colon and squamous cell carcinomas, is notable.

The most constant clinical feature of paraneoplastic pemphigus is the presence of intractable stomatitis. Severe stomatitis is usually the earliest presenting sign and, after treatment, it is the one that persists and is extremely resistant to therapy. This stomatitis consists of erosions and ulcerations that affect all surfaces of the oropharynx and characteristically extend onto the vermilion lip (Fig. 29.10). Most patients also have a severe pseudomembranous conjunctivitis, which may progress to scarring and obliteration of the conjunctival fornices. Nasopharyngeal, esophageal, vaginal, labial, penile, and perianal lesions may also be seen.

Cutaneous findings are quite polymorphic and may present as erythematous macules, flaccid blisters and erosions resembling pemphigus vulgaris, tense blisters resembling bullous pemphigoid, erythema multiforme-like lesions, and lichenoid eruptions. The occurrence of blisters and erythema multiforme-like lesions on the palms and soles is often used to differentiate paraneoplastic pemphigus from pemphigus vulgaris, in which lesions on the palms and soles are unusual. In the chronic form of the disease, a lichenoid eruption may predominate over blistering lesions. Some patients with paraneoplastic pemphigus develop bronchiolitis obliterans, which can be fatal as a result of respiratory failure[50]. Although its pathophysiologic mechanism is still unclear, ectopic expression of epidermal antigens in the setting of squamous metaplasia is thought to render the lung a target organ[51]. Of note, a chest X-ray or CT scan obtained at the onset of bronchiolitis obliterans may be normal but pulmonary function tests will show small airway obstruction that does not reverse with bronchodilators.

Fig. 29.10 Paraneoplastic pemphigus. A The characteristic clinical feature is severe intractable stomatitis with multiple erosions; there may be a resemblance to erosive oral lichen planus. **B** The erosions, along with hemorrhagic crusts, can extend onto the vermilion lip and involve the nasal mucosa. **C** Papulosquamous lichenoid lesions, reflecting an interface dermatitis, can also be present. *A, Courtesy Luis Requena, MD; C, Courtesy Jennie Clarke, MD.*

IgA Pemphigus

IgA pemphigus represents a more recently characterized group of autoimmune intraepidermal blistering diseases presenting with a vesiculopustular eruption, neutrophilic infiltration of the skin, and *in vivo* bound and circulating IgA autoantibodies against the cell surface of keratinocytes; no IgG autoantibodies are present. IgA pemphigus usually occurs in middle-aged or elderly persons. Two distinct types of IgA pemphigus have been described: the *subcorneal pustular dermatosis type* and the *intraepidermal neutrophilic type*. Patients with both types of IgA pemphigus present with flaccid vesicles or pustules on either erythematous or normal skin (Fig. 29.11A). In both types, the pustules tend to coalesce to form an annular or circinate pattern with crusts in the center of the lesion (Fig. 29.11B), although a sunflower-like configuration of pustules is a characteristic sign of the intraepidermal neutrophilic type.

The most common sites of involvement are the axilla and groin, but lesions can also develop on the trunk and proximal extremities. Mucous membrane involvement is rare, and pruritus is often a significant symptom. In some patients, there is an underlying associated disorder such as IgA myeloma or ulcerative colitis. Because the subcorneal pustular dermatosis type of IgA pemphigus is clinically and

Downloaded for Anonymous User (n/a) at Egyptian Knowledge Bank from ClinicalKey.com by Elsevier on March 10, 2024. For personal use only. No other uses without permission. Copyright ©2024. Elsevier Inc. All rights reserved.

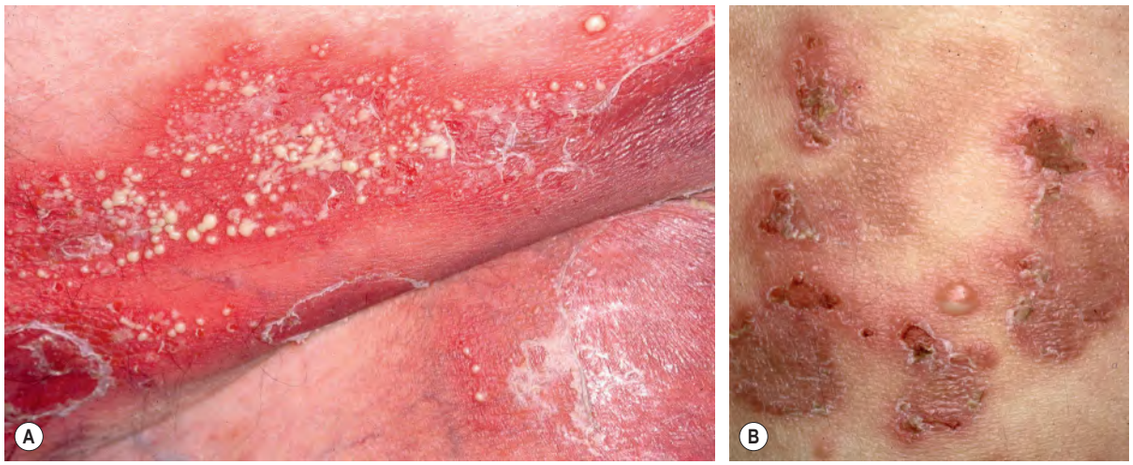

Fig. 29.11 IgA pemphigus – subcorneal pustular dermatosis (SPD) type. A Numerous superficial pustules arising within areas of erythema; these pustules rupture easily. The desquamation has a figurate configuration and overall there is a resemblance to pustular psoriasis. **B** Pustules tend to coalesce to form an annular or figurate pattern with crusts present centrally. Note the accumulation of the pustular component in the dependent portion of the vesiculopustule. *A, Courtesy Luis Requena, MD.*

histologically indistinguishable from classic subcorneal pustular dermatosis (Sneddon–Wilkinson disease; see Ch. 8), immunologic evaluation is essential to differentiate the two diseases.

IgA deposition on cell surfaces of epidermal keratinocytes is present in all cases, as shown by direct immunofluorescence (DIF) microscopy, and many patients have detectable circulating IgA autoantibodies, as shown by indirect immunofluorescence (IIF) microscopy. In the subcorneal pustular dermatosis type, IgA autoantibodies tend to react against upper epidermal surfaces, while in the intraepidermal neutrophilic type, IgA autoantibodies are found throughout the entire epidermis. The subclass of IgA autoantibodies is exclusively IgA1. IgA autoantibodies in the subcorneal pustular dermatosis type were shown to recognize desmocollin 1[52], while the autoimmune targets of the intraepidermal neutrophilic type remain to be identified. A subset of IgA pemphigus patients have IgA autoantibodies directed against Dsg1 or Dsg3, making the autoimmune targets of IgA pemphigus more heterogeneous. Besides the two major forms of IgA pemphigus, some authors include three additional forms of IgA pemphigus – IgA pemphigus foliaceus, IgA pemphigus vulgaris, and IgA pemphigus vegetans. The exact pathogenic role of IgA autoantibodies in inducing pustular formation in IgA pemphigus remains to be elucidated.

PATHOLOGY

For routine histology, it is best to perform biopsies of early lesions. If the vesicle or edematous papule is small enough, the entire lesion can be removed. Otherwise, the biopsy specimen should include the edge of a fresh vesicle or bulla plus the inflammatory rim (Fig. 29.12). Examination of perilesional, rather than lesional, skin is recommended for DIF in order to avoid negative staining due to secondary degeneration of target antigens and immunoreactants. In patients with only mucosal lesions, the biopsy specimen should consist of the active border of a denuded area, since intact blisters are rarely encountered. Cytologic examination (Tzanck smear) is useful for the rapid demonstration of acantholytic epidermal cells within the blister cavity. However, this bedside test merely represents a preliminary diagnostic tool and it should not supplant histologic examination. This is because acantholytic keratinocytes are occasionally seen in various non-acantholytic vesiculobullous or pustular diseases as a result of secondary acantholysis.

Pemphigus Vulgaris

The characteristic histologic finding in this form of pemphigus is intraepidermal blister formation due to a loss of cell–cell adhesion of keratinocytes (acantholysis) without keratinocyte necrosis (Fig. 29.13A). Whereas acantholysis usually occurs just above the basal cell layer (suprabasilar acantholysis), intraepithelial separation may occasionally be higher in the stratum spinosum. A few rounded-up (acantholytic) keratinocytes as well as clusters of epidermal cells are often seen within the blister cavity. Although the basal cells lose lateral desmosomal contact with their neighbors, they maintain their attachment to the basement membrane via *hemidesmosomes*, thus giving the appearance of a "row of tombstones" (Fig. 29.13B). The acantholytic process may involve hair follicles.

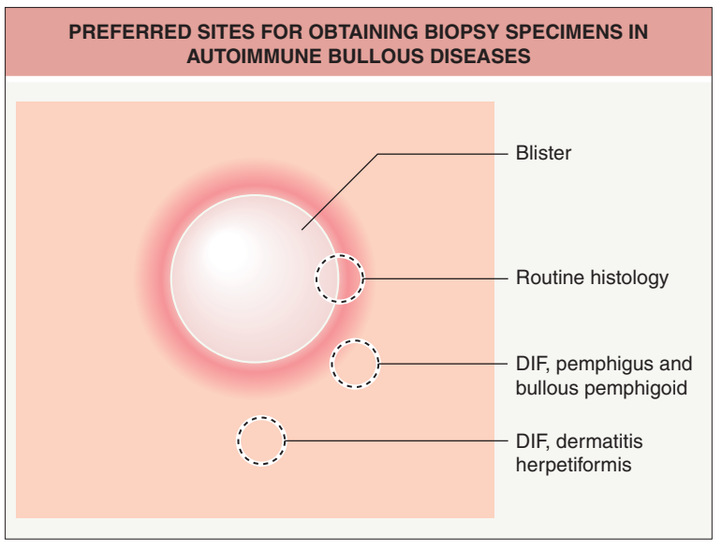

Fig. 29.12 Preferred sites for obtaining biopsy specimens in autoimmune bullous diseases. If the lesion is small enough, the entire vesicle can be removed for routine histology. If the lesions are not small, the edge of a fresh vesicle or bulla plus the inflammatory rim is recommended. For direct immunofluorescence (DIF) for various forms of pemphigus and bullous pemphigoid, perilesional skin is preferred, whereas nearby normal skin is recommended in dermatitis herpetiformis.

The dermal papillary outline is usually maintained and, frequently, the papillae protrude into the blister cavity. The blister cavity may contain a few inflammatory cells, notably eosinophils, and in the dermis there is a moderate perivascular mononuclear cell infiltrate with conspicuous eosinophils. In rare instances, the earliest histologic finding consists of eosinophilic spongiosis (Table 29.4), in which eosinophils infiltrate a spongiotic epidermis with little or no evidence of acantholysis.

In pemphigus vegetans, suprabasilar acantholysis is seen, in addition to considerable papillomatosis and acanthosis. Characteristically, there is an intense inflammatory cell infiltrate containing numerous eosinophils, and intraepidermal microabscesses of eosinophils are often seen.

Pemphigus Foliaceus

The histologic changes of pemphigus foliaceus, pemphigus erythematosus, and fogo selvagem are identical. Early blisters in pemphigus foliaceus have acantholysis in the upper epidermis, within or adjacent to the granular layer (Fig. 29.14). Because the blisters are superficial and fragile, it is often difficult to obtain an intact lesion for histologic examination. As a result, acantholysis is sometimes difficult to detect, but usually a few acantholytic keratinocytes can be found attached to the roof or floor of the blister. Of note, these cells are often almond- or spindle-shaped rather than round. When the blisters form within the granular layer, a "missing" horny layer with a few acantholytic keratinocytes

Downloaded for Anonymous User (n/a) at Egyptian Knowledge Bank from ClinicalKey.com by Elsevier on March 10, 2024. For personal use only. No other uses without permission. Copyright ©2024. Elsevier Inc. All rights reserved.

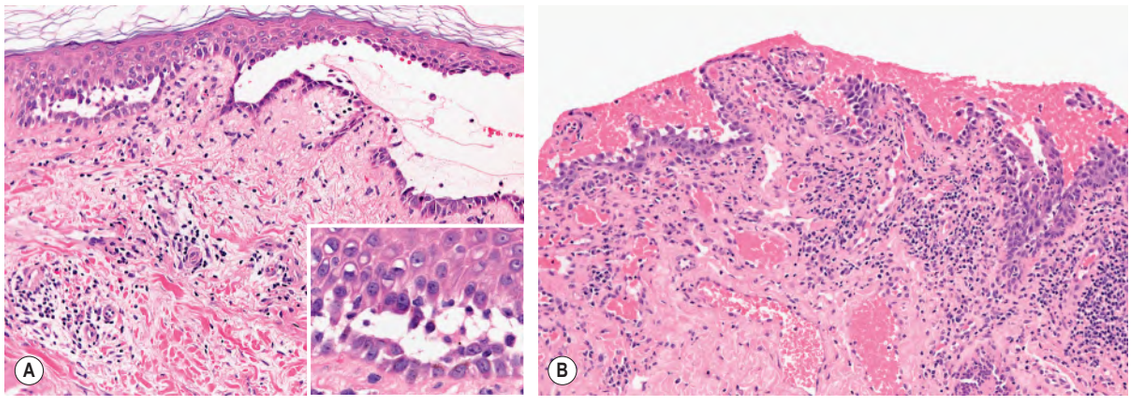

Fig. 29.13 Pemphigus vulgaris – histopathologic features. **A** Blisters in the skin show suprabasilar acantholysis with a few acantholytic cells in the blister cavity (inset). **B** Because blisters in the mouth rarely remain intact, the blister roof is often not seen in oral biopsy specimens. Nonetheless, the diagnosis can be made by the location of the split within the epithelium, the presence of acantholytic cells, and the "tombstones" appearance of the basal cells. *Courtesy Lorenzo Cerroni, MD.*

CAUSES OF EOSINOPHILIC SPONGIOSIS	
• Pemphigus vulgaris and its variants • Pemphigus foliaceus • Bullous pemphigoid and its variants • Pemphigoid gestationis (herpes gestationis) • Mucous membrane (cicatricial) pemphigoid • Linear IgA bullous dermatosis	• Arthropod-bite reactions, including scabies • Drug eruptions • Id reactions • Wells syndrome • Polymorphic eruption of pregnancy • Erythema toxicum neonatorum • Incontinentia pigmenti (first stage) • Atopic dermatitis • Contact dermatitis • Eosinophilic folliculitis • Mycosis fungoides • Prurigo pigmentosa • Still disease

Table 29.4 Causes of eosinophilic spongiosis.

may be the only histopathologic finding (the horny layer detaches as a consequence of superficial acantholysis). Although the deeper epidermis usually remains intact, secondary clefts may develop, leading to detachment of the epidermis in its midlevel, but rarely giving rise to limited areas of separation right above the basal layer.

These superficial blisters are histologically indistinguishable from those seen in staphylococcal scalded skin syndrome or bullous impetigo, because Dsg1 is targeted in both of these diseases[31]. Sometimes the blister cavity contains numerous acute inflammatory cells, particularly neutrophils. Eosinophilic spongiosis can be also seen in very early lesions of pemphigus foliaceus (see Table 29.4). The dermis shows a moderate number of inflammatory cells, among which eosinophils are often present.

Paraneoplastic Pemphigus

The histologic findings of cutaneous lesions in paraneoplastic pemphigus show considerable variability, reflecting the polymorphism seen clinically. The lesions show a unique combination of pemphigus vulgaris-like, erythema multiforme-like, and lichen planus-like histologic features, sometimes in the same specimen (Fig. 29.15). Intact cutaneous blisters demonstrate suprabasilar acantholysis and individual keratinocyte necrosis as well as lymphocytes within the epidermis. In addition, features of an interface dermatitis can be seen, including basal cell liquefactive degeneration or a dense band-like lymphocytic infiltrate in the upper dermis. Eosinophils are rare. Biopsy specimens of the severe ulcerative stomatitis usually yield only nonspecific changes of inflammation, but the perilesional oral epithelium should show suprabasilar acantholysis.

IgA Pemphigus

The characteristic histologic feature in IgA pemphigus is formation of an intraepidermal pustule or vesicle (Fig. 29.16). The contents of the pustules consist predominantly of neutrophils. Acantholysis is usually not seen. IgA pemphigus is divided into two subtypes depending on the

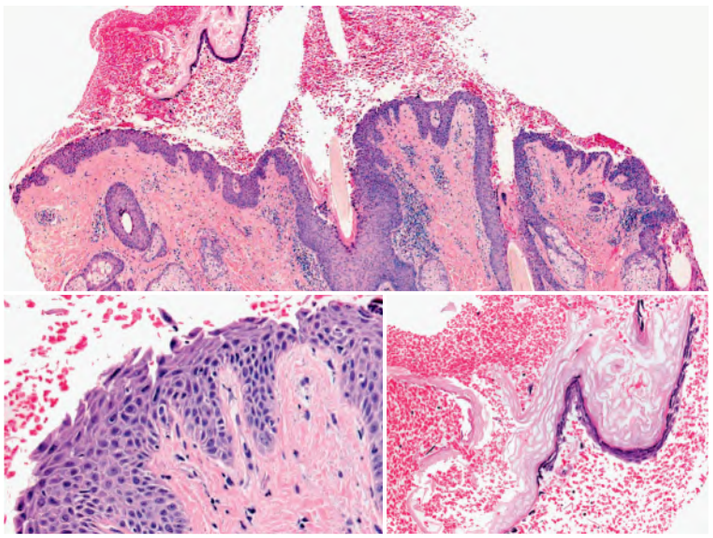

Fig. 29.14 Pemphigus foliaceus – histopathologic features. Because of the fragility of the blisters, the blister roof may become detached (right inset). The split is in the upper spinous layer of the epidermis and acantholytic cells are readily apparent (left inset). *Courtesy Lorenzo Cerroni, MD.*

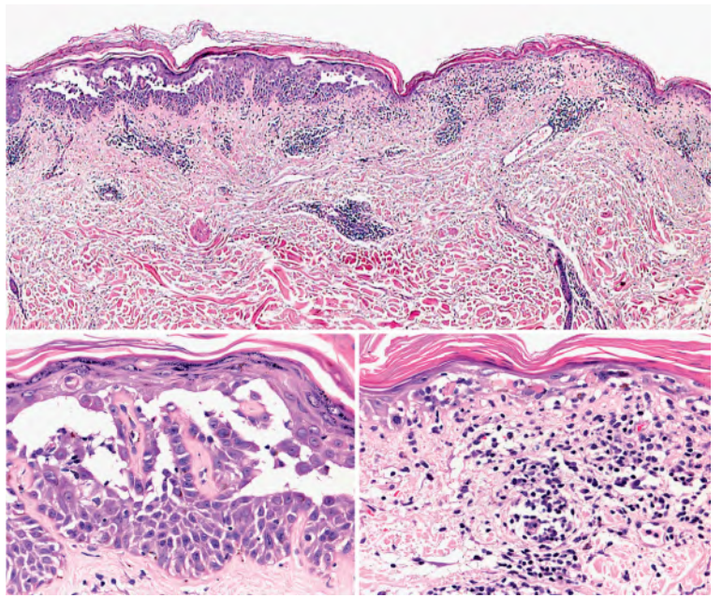

Fig. 29.15 Paraneoplastic pemphigus – histopathologic features. In the same biopsy specimen, there are areas of suprabasilar acantholysis (left inset) as well as an interface dermatitis with basal cell vacuolar change, necrotic keratinocytes, and lymphocytes within the epidermis (right inset). *Courtesy Lorenzo Cerroni, MD.*

Downloaded for Anonymous User (n/a) at Egyptian Knowledge Bank from ClinicalKey.com by Elsevier on March 10, 2024. For personal use only. No other uses without permission. Copyright ©2024. Elsevier Inc. All rights reserved.

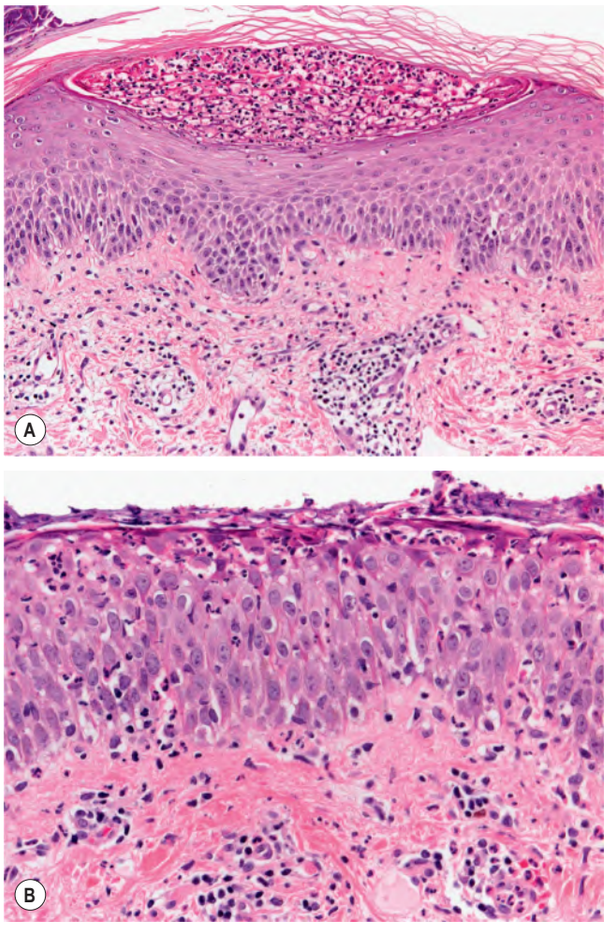

Fig. 29.16 IgA pemphigus – histopathologic features. Intraepidermal pustule with neutrophils present subcorneally in the subcorneal pustular dermatosis type (**A**), and within the entire epidermis in the intraepidermal neutrophilic type (**B**). *Courtesy Lorenzo Cerroni, MD.*

level of intraepidermal pustule; in the subcorneal pustular dermatosis type, pustules are located subcorneally in the upper epidermis, while in the intraepidermal neutrophilic type, suprabasilar pustules involving the lower or entire epidermis are present.

DIFFERENTIAL DIAGNOSIS

Demonstration of IgG (or IgA for IgA pemphigus) autoantibodies directed against the cell surface of keratinocytes is the gold standard for the diagnosis of pemphigus. By detection of these autoantibodies, pemphigus can be differentiated from other vesiculobullous or pustular diseases. Methods for demonstrating pemphigus autoantibodies include DIF, IIF, immunoprecipitation, immunoblotting, and enzyme-linked immunosorbent assay (ELISA).

DIF examines patients' skin or mucous membranes in order to demonstrate *in vivo* bound IgG deposition on the keratinocyte cell surfaces (Fig. 29.17A). The biopsy specimen should be taken from perilesional normal skin or mucous membrane (see Fig. 29.12). DIF is the most reliable and sensitive diagnostic test for all forms of pemphigus. However, on occasion, nonspecific cell surface staining may occur in other skin diseases, such as spongiotic dermatitis, burns, toxic epidermal necrolysis, systemic LE and lichen planus, or in patients with antibodies directed against blood groups A and B. If the DIF is negative, the diagnosis of pemphigus should be seriously questioned. IgG deposition is seen in up to 100% of patients with active pemphigus vulgaris and pemphigus foliaceus. IgM deposition is not found, but occasionally IgA deposition may also be seen. Complement (C3) deposition is not necessarily observed, probably because the dominant subclass of IgG is IgG4, which does not fix complement. The staining pattern of paraneoplastic pemphigus shows deposition of IgG and C3 on epidermal cell surfaces as well as variably along the basement membrane zone. In IgA pemphigus, IgA (but not IgG) deposition is detected on keratinocyte cell surfaces.

IIF examines patients' sera in order to demonstrate circulating IgG autoantibodies directed against epithelial cell surfaces (Fig. 29.17B). In order to optimize sensitivity, there are recommended substrates based upon the particular autoantibody (Table 29.5)[53]. Except for a few patients with early localized disease or those in remission, most patients with pemphigus have circulating anti-epithelial cell surface IgG as determined by IIF. Despite the different antigens involved in pemphigus vulgaris and foliaceus, the staining pattern obtained by DIF or IIF is similar, which makes it difficult to serologically distinguish the two diseases (compare Fig. 29.1B & C). Immunoprecipitation, immunoblotting, and ELISA can be used to demonstrate the target molecules of these autoantibodies.

Immunoprecipitation and immunoblotting detect the target antigens as protein bands of a particular molecular weight that have been separated by electrophoresis (see Ch. 30). Immunoblotting requires denaturation of the protein substrates, but immunoprecipitation does not. Therefore, immunoprecipitation is superior to immunoblotting in detecting antibodies that react with epitopes dependent on three-dimensional structure (conformational epitopes), while immunoblots detect antibodies that react with epitopes that are preserved even after denaturation (linear epitopes). However, an immunoblot is easier to perform because immunoprecipitation requires radioisotopes to label protein substrates.

ELISA is increasingly being used to detect antigen-specific autoantibodies for the diagnosis of pemphigus (Table 29.6)[21,22]. The patient's serum is tested on ELISA plates pre-coated with relevant recombinant proteins, e.g. Dsg1, Dsg3. Thus, specific antibodies directed against Dsg1 or Dsg3 can be detected. This assay has enabled investigators to serologically distinguish subtypes of pemphigus vulgaris and foliaceus. If a serum is positive against Dsg1 but negative against Dsg3, this suggests a diagnosis of pemphigus foliaceus. If negative against Dsg1 but positive against Dsg3, this suggests a diagnosis of the mucosal-dominant type of pemphigus vulgaris. If positive against both Dsg1 and Dsg3, this suggests a diagnosis of mucocutaneous type of pemphigus vulgaris (see Fig. 29.4). Furthermore, ELISA scores demonstrate parallel fluctuations with disease activity and are useful in monitoring disease activity, planning schedules for tapering corticosteroids, and predicting flares or relapses before there is clinical evidence. The *c*hemi*l*uminescent *e*nzyme *i*mmuno*a*ssay (CLEIA) is an even more sensitive and more rapid technique for detecting IgG autoantibodies in patients with pemphigus.

Differential Diagnosis of Pemphigus Vulgaris

Establishing the diagnosis in patients with only oral lesions is more difficult than in those with cutaneous blisters and erosions. The differential diagnosis of mucosal lesions of pemphigus vulgaris includes acute herpetic stomatitis, aphthous stomatitis, erythema multiforme major or Stevens–Johnson syndrome, lichen planus, systemic LE, and mucous membrane (cicatricial) pemphigoid. For cutaneous lesions of pemphigus vulgaris, the differential diagnosis includes other forms of pemphigus, bullous pemphigoid, linear IgA bullous dermatosis, erythema multiforme, Hailey–Hailey disease, and transient acantholytic dermatosis (Grover disease). The differential diagnosis of pemphigus vegetans is outlined in Table 29.7.

The demonstration of IgG autoantibodies against keratinocyte cell surfaces and anti-Dsg3 IgG, as mentioned above, will exclude these diseases (with the exception of drug-induced pemphigus vulgaris and paraneoplastic pemphigus). Fresh blisters of bullous pemphigoid are tense due to a subepidermal split. Hailey–Hailey disease has full-thickness acantholysis ("dilapidated brick wall") with epidermal hyperplasia and an impetiginized scale, and the acantholysis does not extend down follicles as it does in pemphigus. Transient acantholytic dermatosis exhibits only small foci of intraepidermal acantholysis in addition to dyskeratosis; the latter is not present in pemphigus.

Differential Diagnosis of Pemphigus Foliaceus

This differential includes other forms of pemphigus, bullous impetigo, subcorneal pustular dermatosis, subacute cutaneous LE, and seborrheic dermatitis. As discussed earlier for pemphigus vulgaris, the demonstration of IgG autoantibodies against epidermal cell surfaces is essential for separating these disorders from the pemphigus

Downloaded for Anonymous User (n/a) at Egyptian Knowledge Bank from ClinicalKey.com by Elsevier on March 10, 2024. For personal use only. No other uses without permission. Copyright ©2024. Elsevier Inc. All rights reserved.

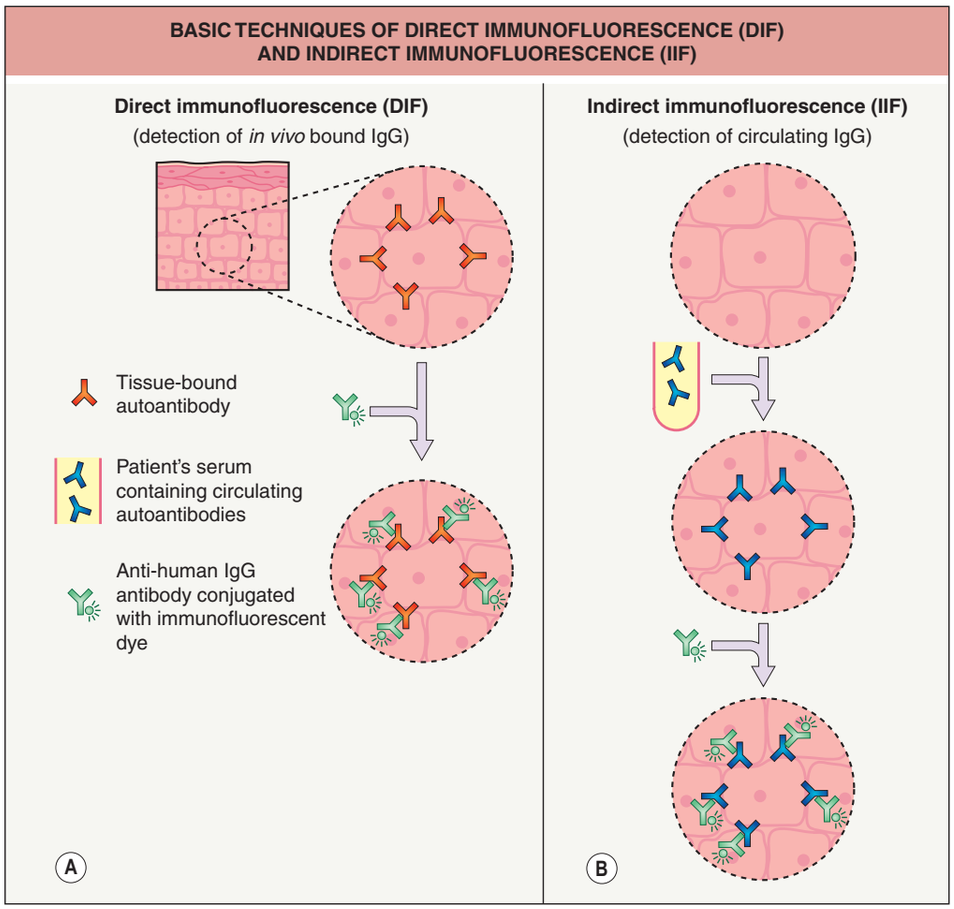

Fig. 29.17 Basic techniques of direct immunofluorescence (DIF) and indirect immunofluorescence (IIF). A DIF is performed on skin biopsy specimens in order to detect *in vivo* bound IgG. **B** IIF is performed utilizing patients' sera in order to detect circulating autoantibodies that bind epithelial antigens.

INDIRECT IMMUNOFLUORESCENCE (IIF) – RECOMMENDED SUBSTRATES

Type of pemphigus	Recommended substrates (autoantibodies)
Pemphigus vulgaris	Monkey esophagus (anti-Dsg3)
Pemphigus foliaceus	Human skin or guinea pig esophagus (anti-Dsg1)
Paraneoplastic pemphigus	Monkey and guinea pig esophagus (anti-Dsg1, anti-Dsg3) Rat bladder (anti-plakin)
Bullous pemphigoid Linear IgA bullous dermatosis	Human skin, salt-split
Mucous membrane (cicatricial) pemphigoid	Human skin, salt-split; normal oral or genital mucosa or conjunctiva

Table 29.5 Indirect immunofluorescence (IIF) for pemphigus and bullous pemphigoid – recommended substrates.

ELISA TO DETECT IgG AUTOANTIBODIES IN AUTOIMMUNE BULLOUS DISEASES – AVAILABLE TARGET AUTOANTIGENS

Target autoantigen	Autoimmune bullous diseases					
	PV	PF	PNP	BP	MMP	EBA
Dsg1	✓	✓	✓			
Dsg3	✓		✓			
BP180				✓	✓	
BP230			✓	✓	✓	
Laminin 332					✓	
Type VII collagen					✓	✓
Envoplakin			✓			
Periplakin			✓			

Table 29.6 ELISA to detect IgG autoantibodies in autoimmune bullous diseases – available target autoantigens. For BP180, the NC16A domain is utilized and for BP230, the N- and/or C-terminus. BP, bullous pemphigoid; EBA, epidermolysis bullosa acquisita; MMP, mucous membrane pemphigoid; PF, pemphigus foliaceus; PNP, paraneoplastic pemphigus; PV, pemphigus vulgaris.

family. A complete review of medications should be done to exclude the possibility of drug-induced pemphigus foliaceus. Because the lesions of pemphigus foliaceus may become secondarily infected, the finding of bacteria does not confirm a diagnosis of bullous impetigo. Likewise, a clinical flare or recalcitrant disease may represent a superimposed disorder, e.g. tinea corporis, especially in patients on systemic corticosteroids.

Differential Diagnosis of Paraneoplastic Pemphigus

This differential includes pemphigus vulgaris, mucous membrane pemphigoid, erythema multiforme or Stevens–Johnson syndrome, lichen planus, GVHD, persistent HSV infection, and other viral infections; stomatitis due to chemotherapy will be limited in duration (7–14 days) (Table 29.8). In two-thirds of patients with paraneoplastic pemphigus, it arises in the context of a known underlying neoplasm, usually a lymphoproliferative disorder, which may have been treated for years before the mucocutaneous lesions appear. In approximately one-third of patients, the underlying neoplasm is undiagnosed at the time the mucocutaneous disease develops. In these latter patients, examination for an occult neoplasm is required, and, given the most commonly associated ones (see earlier), a CT scan of the chest, abdomen, and pelvis should accompany a complete blood count, flow cytometry of peripheral blood, LDH, and serum protein and immunofixation electrophoreses. Severe intractable stomatitis that extends onto the vermilion lip is a key clinical feature in differentiating paraneoplastic pemphigus from

Downloaded for Anonymous User (n/a) at Egyptian Knowledge Bank from ClinicalKey.com by Elsevier on March 10, 2024. For personal use only. No other uses without permission. Copyright ©2024. Elsevier Inc. All rights reserved.

PEMPHIGUS VEGETANS – DIFFERENTIAL DIAGNOSIS	
Major entities	
Hailey–Hailey disease	Vegetative lesions also seen when Darier disease involves intertriginous zones; see Ch. 59
Pemphigoid vegetans	Especially in major body folds; see Fig. 30.6C
Blastomycosis-like pyoderma	Vegetating plaques due to inflammatory reaction to bacterial infection, most commonly *Staphylococcus aureus*; immunosuppression, systemic or local, a risk factor
Pyodermatitis–pyostomatitis vegetans	Form of pyoderma gangrenosum; see Ch. 25
Other entities	
Halogenoderma	
Infections Bacterial – granuloma inguinale, condylomata lata Fungal – dimorphic, chromomycosis Viral – condylomata acuminata, herpes simplex vegetans, chronic verrucous herpes zoster* Parasitic – amebic granuloma	
Buschke–Löwenstein tumors Extramammary Paget disease	
*Occurs in immunocompromised hosts.	

Table 29.7 Pemphigus vegetans – differential diagnosis.

DISORDERS WITH HEMORRHAGIC CRUSTS OF THE VERMILION LIPS	
• Herpes simplex • Herpes zoster	
• Erythema multiforme major • *Mycoplasma*-induced rash and mucositis (MIRM)* • Stevens–Johnson syndrome/toxic epidermal necrolysis spectrum	
• Pemphigus vulgaris • Paraneoplastic pemphigus	
• Contact cheilitis	
*Also referred to as reactive infectious mucocutaneous eruption (RIME).	

Table 29.8 Disorders with hemorrhagic crusts of the vermilion lips. *Photograph: Courtesy Jeffrey P. Callen, MD.*

THERAPEUTIC LADDER FOR PEMPHIGUS VULGARIS	
Standard treatment	
Oral prednisone	1 mg/kg/day as an initial dose (usually 60 mg/day) (1)
Rituximab	375 mg/m^2 once weekly for 4 weeks or 1 g initially then at two weeks; either regimen may need to be repeated every 3–6 months (1)
Aggressive treatment	
Immunosuppressive agents in combination with oral prednisone:	
Azathioprine	2–4 mg/kg/day (usually 100 to 300 mg/day) (1)
Mycophenolate mofetil	2–3 g/day (2)
Cyclophosphamide	1–3 mg/kg/day (usually 50 to 200 mg/day) (2)
Cyclosporine	3–5 mg/kg/day (2)*
Pulse methylprednisolone	1 g/day over a period of 2–3 hours for 3–5 consecutive days (2)
Methotrexate	7.5–20 mg/week (2)
Pulse cyclophosphamide	500–1000 mg/m^2 every 4 weeks (3)
Plasmapheresis	1–2 times per week, at the onset (2)
High-dose IVIg	400 mg/kg/day for 5 consecutive days (1); may need to be repeated monthly
Extracorporeal photopheresis	2 days per month (3)
Topical treatment	
• Topical corticosteroids (1), especially Class I to localized persistent sites	
• Topical antibiotics (2)	
• Topical immunomodulators (e.g. cyclosporine, tacrolimus) (3)	
Intralesional therapy	
• Corticosteroids (3)	
• Rituximab (5 mg/cm^2) (3)	
*In one trial, shown not to be of benefit when added to systemic corticosteroids.	

Table 29.9 Therapeutic ladder for pemphigus vulgaris. Key to evidence-based support: (1) prospective controlled trial; (2) retrospective study or large case series; (3) small case series or individual case reports.

most cases of pemphigus vulgaris or mucous membrane pemphigoid. The gold standard for the diagnosis of paraneoplastic pemphigus is the demonstration of the characteristic combination of IgG autoantibodies – anti-plakin autoantibodies by immunoprecipitation, immunoblotting or ELISA and anti-desmoglein autoantibodies by ELISA (see Table 29.6).

Differential Diagnosis of IgA Pemphigus

The differential diagnosis includes subcorneal pustular dermatosis, pemphigus foliaceus, bullous impetigo, dermatitis herpetiformis, linear IgA bullous dermatosis, and pustular psoriasis. The clinical and histologic features of the SPD type of IgA pemphigus and classic subcorneal pustular dermatosis are indistinguishable. The demonstration of IgA autoantibodies is essential for separating these other disorders from IgA pemphigus.

TREATMENT

Pemphigus Vulgaris

Before the advent of systemic corticosteroids, pemphigus vulgaris was usually a fatal disease; most patients died within 2–5 years of the onset of the disease because large areas of the skin lost their epidermal barrier function, leading to the loss of body fluids or to secondary bacterial infections. Pemphigus foliaceus had a better prognosis, except for the occasional acute cases with generalized involvement. Because pemphigus is caused by pathogenic autoantibodies, therapy must be designed to reduce autoantibody production, not just to suppress local inflammation. The introduction of systemic corticosteroids and immunosuppressive agents has greatly improved the prognosis of pemphigus; however, the morbidity, and occasional mortality, is still significant due to complications of therapy. Systemic corticosteroids are the mainstay of therapy for pemphigus. Immunosuppressive agents are often used for their corticosteroid-sparing effect in order to reduce the side effects of the corticosteroids (Table 29.9), with the goal of therapy being to control the disease with the lowest possible dose of corticosteroids. High-dose IVIg, which is non-immunosuppressive, and anti-CD20 monoclonal antibodies have been recently added to the therapeutic armamentarium for pemphigus. Introduction of PDAI (pemphigus disease area index) and ABSIS (autoimmune bullous skin disorder intensity score) allow for more standardized assessment of disease extent and response to treatment[54].

Systemic corticosteroid therapy, usually in the form of oral prednisone, is standard treatment (see Ch. 125). Prednisone at 1 mg/kg/day (usually 60 mg/day) is a typical initial dosage. The therapeutic effects are clinically estimated by the number of new blisters per day and the rate of healing of new lesions, and the prednisone is then gradually tapered. Once clinical remission is obtained, changes in the titer of circulating autoantibodies, as determined by IIF or ELISA, are helpful in gauging the dose of prednisone[22]. If there is no response in 3–7 days, other options may be employed, as discussed below. Intravenous pulse therapy with 1 g/day methylprednisolone (over a period of 2–3 hours, with continuous cardiac monitoring) for 3–5 consecutive days is an alternative choice for severe cases.

Downloaded for Anonymous User (n/a) at Egyptian Knowledge Bank from ClinicalKey.com by Elsevier on March 10, 2024. For personal use only. No other uses without permission. Copyright ©2024. Elsevier Inc. All rights reserved.

In general, immunosuppressive agents, such as *azathioprine*, *mycophenolate mofetil* and *cyclophosphamide*, when combined with corticosteroids, may result in gaining early control of the disease and an increased percentage of clinical remissions[55–60]. For example, in patients with mild to moderate disease who received corticosteroids plus either placebo or mycophenolate mofetil in a prospective, randomized trial, the latter group showed faster and more durable responses[61]. Azathioprine is used at a dose of 2–4 mg/kg/day (usually 100–300 mg/day) and its major side effects are nausea and dose-dependent myelosuppression (see Ch. 130). Mycophenolate mofetil is used at a dose of 2–3 g/day and it has a similar action to azathioprine, with less myelosuppression but more gastrointestinal toxicity[58]. Cyclophosphamide is given at a dose of 1–3 mg/kg/day (usually 50–200 mg/day) orally or 500–1000 mg/m^2 every four weeks intravenously and its major side effects are hemorrhagic cystitis, sterility and leukopenia, with an increased risk of bladder carcinoma long-term; there is a movement away from lower doses of daily cyclophosphamide in an effort to possibly reduce the risk of bladder cancer. Chlorambucil, like cyclophosphamide, is an alkylating agent and although there is no bladder toxicity, side effects include myelosuppression and long-term an increased risk of developing leukemia.

If complete remission is achieved with the combined therapy, the dosage of the immunosuppressive drug is maintained while the prednisone is slowly tapered; when a dose of 5–10 mg/day is reached, careful taper then discontinuation of the immunosuppressive drug is attempted. In young patients, the potential increase in malignancies that might be associated with the use of these drugs must be taken into account. In some patients, especially those who are elderly with limited disease or those in whom corticosteroids are contraindicated, immunosuppressive agents alone may be used.

While *cyclosporine* (3–5 mg/kg/day) has been used as an immunosuppressive agent in some patients with pemphigus vulgaris, a randomized trial found that the addition of cyclosporine to corticosteroids did not offer a benefit. Also, *gold* is rarely utilized nowadays.

Plasmapheresis is useful for quickly reducing the titers of circulating autoantibodies and should be considered for severe pemphigus if the disease is unresponsive to a combination of prednisone and immunosuppressives[59]. Concomitant immunosuppression with corticosteroids and cyclophosphamide prevents a post-plasmapheresis rebound increase in the production of autoantibody.

High-dose IVIg is another option for resistant disease. IVIg is a blood product prepared from pooled plasma that has immunomodulatory effects when used in a high dose. It is thought to exert its effect via multiple modes of action, including modulation of expression and function of Fc receptors and the cytokine network; provision of anti-idiotypic antibodies; and modulation of dendritic cell, T cell, and B cell activation, differentiation, and effector functions[62]. A multicenter, randomized, placebo-controlled, double-blind trial demonstrated that high-dose IVIg is an effective and safe treatment for steroid-resistant pemphigus[63].

Rituximab is a potent B cell-depleting chimeric anti-CD20 monoclonal antibody that was first used to treat B cell malignancies, but increasingly is used for a variety of autoimmune diseases, including pemphigus. CD20 is a transmembrane glycoprotein specifically expressed on B cells (from the pre-B stage in the bone marrow to the activated and memory B stage in blood or secondary lymphoid organs), but its expression is lost upon plasma cell differentiation[64]. Rituximab seems not only to induce a depletion of $CD20^+$ B cells and a decline in IgG (including anti-desmoglein autoantibodies), but also decreases desmoglein-specific T cells[65]. When used as adjuvant therapy in non-randomized prospective studies, rituximab led to a complete remission in most of the patients with refractory pemphigus vulgaris and foliaceus[66–68]. A prospective, open-label, randomized trial demonstrated that as an adjuvant therapy rituximab led to a greater proportion of patients achieving complete remission off-therapy, compared with corticosteroid treatment alone[69]. The US FDA has approved rituximab for moderate-to-severe pemphigus and a consensus group has suggested that it be considered early in the course of disease rather than just for patients with recalcitrant disease[60]. The side effects of rituximab, including infusion reactions, reactivation of hepatitis B virus, and progressive multifocal leukoencephalopathy, are discussed in Chapter 128. Because rituximab is a chimeric biologic agent, patients may develop anti-drug antibodies and in theory a lower therapeutic response. As in primary cutaneous B cell lymphoma, there are reports of the use of intralesional injections of rituximab for refractory pemphigus vulgaris[70]. Humanized anti-CD20 antibodies, e.g. obinutuzumab, ofatumumab, may become alternative options for B cell depletion.

Desmoglein-specific immune suppression, via targeting T cells or B cells, would represent an ideal therapeutic strategy given that the target antigens and pathophysiological mechanisms of pemphigus have been well characterized. In 2020, the FDA granted DSG3-CAART, which targets Dsg3-specific B cells[71], orphan drug designation for the treatment of pemphigus vulgaris. Lastly, in a recent phase II trial, efgartigimod, an inhibitor of the neonatal Fc-receptor (FcRn) led to early disease control in 28 of 31 patients with either pemphigus vulgaris or pemphigus foliaceus[72].

Pemphigus Foliaceus

When pemphigus foliaceus is active and widespread, the treatment is, in general, similar to that for pemphigus vulgaris. In some patients, pemphigus foliaceus may be localized for many years; they do not necessarily have to be treated with systemic therapy, and superpotent topical corticosteroids may be sufficient to control the disease. Dapsone can also be used when neutrophils are dominant histologically.

Paraneoplastic Pemphigus

Patients with benign tumors, such as thymomas or localized Castleman disease, should have the tumor surgically excised. The majority of these patients will either improve substantially or clear completely. However, it may take 6–18 months to see complete resolution of lesions after excision of a benign neoplasm. In patients with malignant neoplasms, there is no consensus on a standard effective therapeutic regimen. Administration of tumor-specific chemotherapy or targeted therapy may result in complete resolution of the malignancy and a slow resolution of the skin lesions. Cutaneous lesions respond more rapidly to therapy, in contrast to the stomatitis, which is generally refractory to most forms of treatment. Overall, the prognosis of paraneoplastic pemphigus is poor due to its resistant nature to treatment.

IgA Pemphigus

Dapsone is the drug of choice for most patients with IgA pemphigus. A clinical response usually occurs within 24–48 hours. If dapsone is not well tolerated, sulfapyridine and acitretin are useful alternatives. Occasionally, those drugs are not effective, and low- to medium-dose prednisone may be considered, as well as photochemotherapy (PUVA) or colchicine.

Additional figures available in our eBook (see inside front cover for access code).

REFERENCES

1. Payne AS, Stanley JR. Pemphigus. In: Kong S, Amagai M, Bruckner AL, eds. *Fitzpatrick's Dermatology*. 9th ed. New York: McGraw-Hill; 2019:909–933.
2. Kasperkiewicz M, Ellebrecht CT, Takahashi H, et al. Pemphigus. *Nat Rev Dis Pri*. 2017;3:1–18.
3. Anhalt GJ, Kim S, Stanley JR, et al. Paraneoplastic pemphigus. An autoimmune mucocutaneous disease associated with neoplasia. *N Engl J Med*. 1990;323:1729–1735.
4. Beutner EH, Jordon RE. Demonstration of skin antibodies in sera of pemphigus vulgaris patients by indirect immunofluorescent staining. *Proc Soc Exp Biol Med*. 1964;117:505–510.
5. Anhalt GJ, Labib RS, Voorhees JJ, et al. Induction of pemphigus in neonatal mice by passive transfer of IgG from patients with the disease. *N Engl J Med*. 1982;306:1189–1196.
6. Stanley JR, Yaar M, Hawley NP, et al. Pemphigus antibodies identify a cell surface glycoprotein synthesized by human and mouse keratinocytes. *J Clin Invest*. 1982;70:281–288.
7. Amagai M, Klaus-Kovtun V, Stanley JR. Autoantibodies against a novel epithelial cadherin in pemphigus vulgaris, a disease of cell adhesion. *Cell*. 1991;67:869–877.
8. Diaz LA, Prisayanh P, Qaqish B, et al. A *Lutzomyia longipalpis* salivary protein induces cross-reactive antibodies to pemphigus autoantigen desmoglein 1. *J Invest Dermatol*. 2020;140:2332–2342.
9. Warren SJ, Lin MS, Giudice GJ, et al. The prevalence of antibodies against desmoglein 1 in endemic pemphigus foliaceus in Brazil. *N Engl J Med*. 2000;343:23–30.
10. Li N, Aoki V, Hans-Filho G, et al. The role of intramolecular epitope spreading in the pathogenesis of endemic pemphigus foliaceus (fogo selvagem). *J Exp Med*. 2003;197:1501–1510.

Downloaded for Anonymous User (n/a) at Egyptian Knowledge Bank from ClinicalKey.com by Elsevier on March 10, 2024. For personal use only. No other uses without permission. Copyright ©2024. Elsevier Inc. All rights reserved.

11. Foster ML, Spaulding RT, Schadt CR. Neonatal pemphigus vulgaris. *JAMA Dermatol*. 2021;157(2):220.
12. Rock B, Labib RS, Diaz LA. Monovalent Fab′ immunoglobulin fragments from endemic pemphigus foliaceus autoantibodies reproduce the human disease in neonatal Balb/c mice. *J Clin Invest*. 1990;85:296–299.
13. Karpati S, Amagai M, Prussick R, et al. Pemphigus vulgaris antigen, a desmoglein type of cadherin, is located within keratinocyte desmosomes. *J Cell Biol*. 1993;122:409–415.
14. Hashimoto T, Ogawa MM, Konohana A, et al. Detection of pemphigus vulgaris and pemphigus foliaceus antigens by immunoblot analysis using different antigen sources. *J Invest Dermatol*. 1990;94:327–331.
15. Korman NJ, Eyre RW, Klaus-Kovtun V, et al. Demonstration of an adhering-junction molecule (plakoglobin) in the autoantigens of pemphigus foliaceus and pemphigus vulgaris. *N Engl J Med*. 1989;321:631–635.
16. Koch PJ, Walsh MJ, Schmelz M, et al. Identification of desmoglein, a constitutive desmosomal glycoprotein, as a member of the cadherin family of cell adhesion molecules. *Eur J Cell Biol*. 1990;53:1–12.
17. Takeichi M. Cadherin cell adhesion receptors as a morphogenetic regulator. *Science*. 1991;251:1451–1455.
18. Honig B, Shapiro L. Adhesion protein structure, molecular affinities, and principles of cell-cell recognition. *Cell*. 2020;181:520–535.
19. Kljuic A, Bazzi H, Sundberg JP, et al. Desmoglein 4 in hair follicle differentiation and epidermal adhesion: evidence from inherited hypotrichosis and acquired pemphigus vulgaris. *Cell*. 2003;113:249–260.
20. Harrison OJ, Brasch J, Lasso G, et al. Structural basis of adhesive binding by desmocollins and desmogleins. *Proc National Acad Sci*. 2016;113:7160–7165.
21. Ishii K, Amagai M, Hall RP, et al. Characterization of autoantibodies in pemphigus using antigen-specific enzyme-linked immunosorbent assays with baculovirus-expressed recombinant desmogleins. *J Immunol*. 1997;159:2010–2017.
22. Amagai M, Komai A, Hashimoto T, et al. Usefulness of enzyme-linked immunosorbent assay (ELISA) using recombinant desmogleins 1 and 3 for serodiagnosis of pemphigus. *Br J Dermatol*. 1999;140:351–357.
23. Amagai M, Hashimoto T, Shimizu N, et al. Absorption of pathogenic autoantibodies by the extracellular domain of pemphigus vulgaris antigen (Dsg3) produced by baculovirus. *J Clin Invest*. 1994;94:59–67.
24. Amagai M, Nishikawa T, Nousari HC, et al. Antibodies against desmoglein 3 (pemphigus vulgaris antigen) are present in sera from patients with paraneoplastic pemphigus and cause acantholysis in vivo in neonatal mice. *J Clin Invest*. 1998;102:775–782.
25. Amagai M, Karpati S, Prussick R, et al. Autoantibodies against the amino-terminal cadherin-like binding domain of pemphigus vulgaris antigen are pathogenic. *J Clin Invest*. 1992;90:919–926.
26. Nagasaka T, Nishifuji K, Ota T, et al. Defining the pathogenic involvement of desmoglein 4 in pemphigus and staphylococcal scalded skin syndrome. *J Clin Invest*. 2004;114:1484–1492.
27. Mahoney MG, Wang Z, Rothenberger KL, et al. Explanation for the clinical and microscopic localization of lesions in pemphigus foliaceus and vulgaris. *J Clin Invest*. 1999;103:461–468.
28. Stanley JR, Amagai M. Pemphigus, bullous impetigo, and the staphylococcal scalded-skin syndrome. *N Engl J Med*. 2006;355:1800–1810.
29. Kubo A, Nagao K, Yokouchi M, et al. External antigen uptake by Langerhans cells with reorganization of epidermal tight junction barriers. *J Exp Med*. 2009;206: 2937–2946.
30. Wu H, Wang ZH, Yan A, et al. Protection against pemphigus foliaceus by desmoglein 3 in neonates. *N Engl J Med*. 2000;343:31–35.
31. Amagai M, Matsuyoshi N, Wang ZH, et al. Toxin in bullous impetigo and staphylococcal scalded skin syndrome targets desmoglein 1. *Nat Med*. 2000;6:1275–1277.
32. Saito M, Stahley SN, Caughman CY, et al. Signaling dependent and independent mechanisms in pemphigus vulgaris blister formation. *PLoS ONE*. 2012;7:e50696.
33. Payne AS, Ishii K, Kacir S, et al. Genetic and functional characterization of human pemphigus vulgaris monoclonal autoantibodies isolated by phage display. *J Clin Invest*. 2005;115:888–899.
34. Tsunoda K, Ota T, Aoki M, et al. Induction of pemphigus phenotype by a mouse monoclonal antibody against the amino-terminal adhesive interface of desmoglein 3. *J Immunol*. 2003;170:2170–2178.
35. Koch PJ, Mahoney MG, Ishikawa H, et al. Targeted disruption of the pemphigus vulgaris antigen (desmoglein 3) gene in mice causes loss of keratinocyte cell adhesion with a phenotype similar to pemphigus vulgaris. *J Cell Biol*. 1997;137:1091–1102.
36. Delva E, Jennings JM, Calkins CC, et al. Pemphigus vulgaris IgG-induced desmoglein-3 endocytosis and desmosomal disassembly are mediated by a clathrin- and dynamin-independent mechanism. *J Biol Chem*. 2008;283:18303–18313.
37. Schepens I, Jaunin F, Begre N, et al. The protease inhibitor alpha-2-macroglobulin-like-1 is the p170 antigen recognized by paraneoplastic pemphigus autoantibodies in humans. *PLoS ONE*. 2010;18:e12250.
38. Tsuchisaka A, Numata S, Teye K, et al. Epiplakin is a paraneoplastic pemphigus autoantigen and related to bronchiolitis obliterans in Japanese patients. *J Invest Dermatol*. 2016;136:399–408.
38a. Landegren N, Ishii N, Aranda-Guillen M, et al. A gene-centric approach to biomarker discovery identifies transglutaminase 1 as an epidermal autoantigen. *Proc Natl Acad Sci USA*. 2021; 118: e2100687118.
39. Takahashi H, Kouno M, Nagao K, et al. Desmoglein 3-specific CD4+ T cells induce pemphigus vulgaris and interface dermatitis in mice. *J Clin Invest*. 2011;121: 3677–3688.
40. Sekiguchi M, Futei Y, Fujii Y, et al. Dominant autoimmune epitopes recognized by pemphigus antibodies map to the N-terminal adhesive region of desmogleins. *J Immunol*. 2001;167:5439–5448.
41. Ahmed AR, Yunis EJ, Khatri K, et al. Major histocompatibility complex haplotype studies in Ashkenazi Jewish patients with pemphigus vulgaris. *Proc Natl Acad Sci USA*. 1990;87:7658–7662.
42. Wucherpfennig KW, Yu B, Bhol K, et al. Structural basis for major histocompatibility complex (MHC)-linked susceptibility to autoimmunity: charged residues of a single MHC binding pocket confer selective presentation of self-peptides in pemphigus vulgaris. *Proc Natl Acad Sci USA*. 1995;92:11935–11939.
43. Lin MS, Swartz SJ, Lopez A, et al. Development and characterization of desmoglein-3 specific T cells from patients with pemphigus vulgaris. *J Clin Invest*. 1997;99: 31–40.
44. Veldman CM, Gebhard KL, Uter W, et al. T cell recognition of desmoglein 3 peptides in patients with pemphigus vulgaris and healthy individuals. *J Immunol*. 2004;172:3883–3892.
45. Amagai M, Tsunoda K, Suzuki H, et al. Use of autoantigen-knockout mice in developing an active autoimmune disease model of pemphigus. *J Clin Invest*. 2000;105:625–631.
46. Senear FE, Usher B. An unusual type of pemphigus combining features of lupus erythematosus. *Arch Dermatol Syphilol*. 1926;13:761–781.
47. Jablonska S, Chorzelski TP, Beutner EH, et al. Herpetiform pemphigus, a variable pattern of pemphigus. *Int J Dermatol*. 1975;14:353–359.
48. Ishii K, Amagai M, Komai A, et al. Desmoglein 1 and desmoglein 3 are the target autoantigens in herpetiform pemphigus. *Arch Dermatol*. 1999;135:943–947.
49. Brenner S, Bialy-Golan A, Ruocco V. Drug-induced pemphigus. *Clin Dermatol*. 1998;16:393–397.
50. Nousari HC, Deterding R, Wojtczack H, et al. The mechanism of respiratory failure in paraneoplastic pemphigus. *N Engl J Med*. 1999;340:1406–1410.
51. Hata T, Nishimoto S, Nagao K, et al. Ectopic expression of epidermal antigens renders the lung a target organ in paraneoplastic pemphigus. *J Immunol*. 2013;191:83–90.
52. Hashimoto T, Kiyokawa C, Mori O, et al. Human desmocollin 1 (Dsc 1) is an autoantigen for the subcorneal pustular dermatosis type of IgA pemphigus. *J Invest Dermatol*. 1997;109:127–131.
53. Sabolinski ML, Beutner EH, Krasny S, et al. Substrate specificity of anti-epithelial antibodies of pemphigus vulgaris and pemphigus foliaceus sera in immunofluorescence tests on monkey and guinea pig esophagus sections. *J Invest Dermatol*. 1987;88:545–549.
54. Rosenbach M, Murrell DF, Bystryn JC, et al. Reliability and convergent validity of two outcome instruments for pemphigus. *J Invest Dermatol*. 2009;129:2404–2410.
55. Aberer W, Wolff SE, Stingl G, Wolff K. Azathioprine in the treatment of pemphigus vulgaris. A long-term follow-up. *J Am Acad Dermatol*. 1987;16:527–533.
56. Fellner MJ, Katz JM, McCabe JB. Successful use of cyclophosphamide and prednisone for initial treatment of pemphigus vulgaris. *Arch Dermatol*. 1978;114:889–894.
57. Fine JD. Management of acquired bullous skin diseases. *N Engl J Med*. 1995;333:1475–1484.
58. Beissert S, Werfel T, Frieling U, et al. A comparison of oral methylprednisolone plus azathioprine or mycophenolate mofetil for the treatment of pemphigus. *Arch Dermatol*. 2006;142:1447–1454.
59. Bystryn JC, Steinman NM. The adjuvant therapy of pemphigus. An update. *Arch Dermatol*. 1996;132:203–212.
60. Murrell DF, Peña S, Joly P, et al. Diagnosis and management of pemphigus: recommendations by an International Panel of Experts. *J Am Acad Dermatol*. 2020;82:575–585.
61. Beissert S, Mimouni D, Kanwar AJ, et al. Treating pemphigus vulgaris with prednisone and mycophenolate mofetil: a multicenter, randomized, placebo-controlled trial. *J Invest Dermatol*. 2010;130:2041–2048.
62. Kazatchkine MD, Kaveri SV. Immunomodulation of autoimmune and inflammatory diseases with intravenous immune globulin. *N Engl J Med*. 2001;345:747–755.
63. Amagai M, Ikeda S, Shimizu H, et al. A randomized double-blind trial of intravenous immunoglobulin for pemphigus. *J Am Acad Dermatol*. 2009;60:595–603.
64. Edwards JC, Cambridge G. B-cell targeting in rheumatoid arthritis and other autoimmune diseases. *Nat Rev Immunol*. 2006;6:394–403.
65. Eming R, Nagel A, Wolff-Franke S, et al. Rituximab exerts a dual effect in pemphigus vulgaris. *J Invest Dermatol*. 2008;128:2850–2858.
66. Ahmed AR, Spigelman Z, Cavacini LA, et al. Treatment of pemphigus vulgaris with rituximab and intravenous immune globulin. *N Engl J Med*. 2006;355:1772–1779.
67. Joly P, Mouquet H, Roujeau JC, et al. A single cycle of rituximab for the treatment of severe pemphigus. *N Engl J Med*. 2007;357:545–552.
68. Colliou N, Picard D, Caillot F, et al. Long-term remissions of severe pemphigus after rituximab therapy are associated with prolonged failure of desmoglein B cell response. *Sci Transl Med*. 2013;5 175ra30.
69. Joly P, Maho-Vaillant M, Prost-Squarcioni C, et al. First-line rituximab combined with short-term prednisone versus prednisone alone for the treatment of pemphigus (Ritux 3): a prospective, multicentre, parallel-group, open-label randomised trial. *Lancet*. 2017;389: 2031–2040.
70. Vinay K, Kanwar AJ, Mittal A, et al. Intralesional rituximab in the treatment of refractory oral pemphigus vulgaris. *JAMA Dermatol*. 2015;151:878–882.
71. Ellebrecht CT, Bhoj VJ, Nace A, et al. Reengineering chimeric antigen receptor T cells for targeted therapy of autoimmune disease. *Science*. 2016;353:179–184.
72. Goebeler M, Bata- Csörgö, De Simone C, et al. Treatment of pemphigus vulgaris and foliaceus with efgartigimod, a neonatal Fc receptor inhibitor: a phase II multicentre, open-label feasibility trial. *Br J Dermatol*. 2022;186: 429–439.

Downloaded for Anonymous User (n/a) at Egyptian Knowledge Bank from ClinicalKey.com by Elsevier on March 10, 2024. For personal use only. No other uses without permission. Copyright ©2024. Elsevier Inc. All rights reserved.

eFig. 29.1 Pemphigus vulgaris. Flaccid blisters and an erosion due to rupture of a bulla.

eFig. 29.2 Pemphigus foliaceus. Multiple erosions as well as thick scale-crusts on the upper back.

eFig. 29.3 Pemphigus foliaceus of the scalp that may be misdiagnosed as sebopsoriasis. *Courtesy Jeffrey P. Callen, MD.*

eFig. 29.4 Pemphigus foliaceus. Generalized erythema with large erosions and widespread scale-crusts. The latter are said to resemble corn flakes.

eFig. 29.5 Paraneoplastic pemphigus. Fragile vesicles and bullae on an inflammatory base. See Figure 29.10C for lichenoid lesions in the same patient. *Courtesy Jennie Clarke, MD.*

eFig. 29.6 IgA pemphigus. Intraepidermal neutrophilic (IEN) type. The characteristic sunflower-like configuration of pustules is seen.

Downloaded for Anonymous User (n/a) at Egyptian Knowledge Bank from ClinicalKey.com by Elsevier on March 10, 2024. For personal use only. No other uses without permission. Copyright ©2024. Elsevier Inc. All rights reserved.

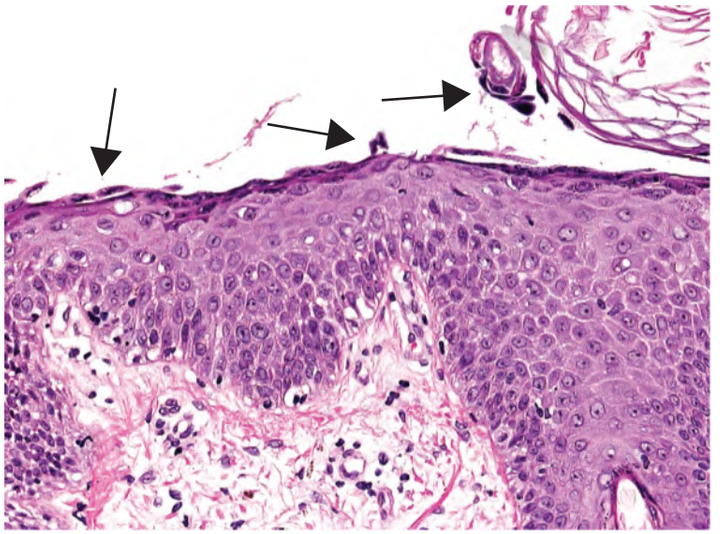

eFig. 29.7 Pemphigus foliaceus – histopathological features. Cleavage within the granular layer results in detachment of the horny layer; note a few acantholytic keratinocytes as a clue (arrows). *Courtesy Lorenzo Cerroni, MD*.

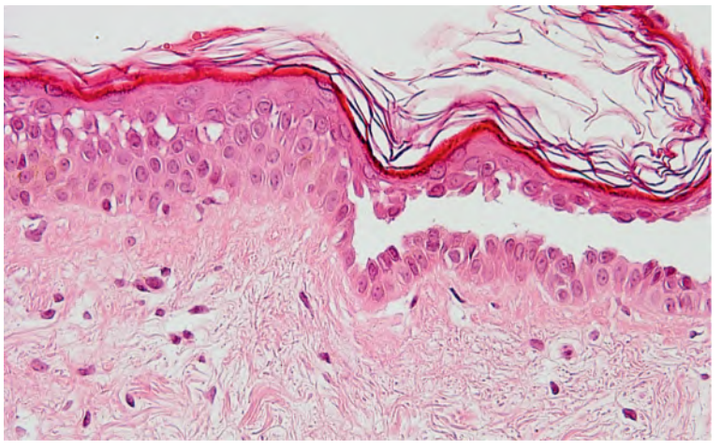

eFig. 29.8 Pemphigus foliaceus – histopathological features. Clefting is seen in the upper spinous layer of the epidermis with several acantholytic cells detaching from the roof of the blister.

Downloaded for Anonymous User (n/a) at Egyptian Knowledge Bank from ClinicalKey.com by Elsevier on March 10, 2024. For personal use only. No other uses without permission. Copyright ©2024. Elsevier Inc. All rights reserved.